

UDK 617.541.1

V. R. Zarembo¹, O. A. Danylov²

Surgical approach to treatment of asymmetric pectus excavatum in children

¹Municipal Non-profit Institution Zhytomyr Regional Children's Clinical Hospital of Zhytomyr Regional Council, Ukraine

²Shupyk National Healthcare University of Ukraine, Kyiv

Paediatric surgery (Ukraine).2022.1(74):27-33; doi 10.15574/PS.2022.74.27

For citation: Zarembo VR, Danylov OA. (2022). Surgical approach to treatment of asymmetric pectus excavatum in children. Paediatric Surgery. (Ukraine). 1 (74): 27-33. doi: 10.15574/PS.2022.74.27.

Objective. To improve the outcomes in patients with asymmetric pectus excavatum (APE) by developing and implementing our own differentiated modified Nuss procedure to correct different variants of this deformity; to analyse the treatment outcomes.

Materials and methods. An original modified Nuss procedure to correct the following pectus excavatum (PE) types is described: asymmetric eccentric focal (IIA1 according to Park) type; asymmetric eccentric broad-flat (Park IIA2) type; asymmetric eccentric long canal (the Grand Canyon type or Park IIA3) type; asymmetric unbalanced (Park IIB) type; asymmetric combined (Park IIC) type. The essence of the proposed technique is that at the beginning of the operation, a gradual elevation of the anterior chest wall is carried out to a maximally approximated physiological position using two or more traction ligatures applied to the sternum and ribs. In the future, a horizontal position of the fixation bar is used for asymmetric eccentric focal, asymmetric eccentric broad-flat, and asymmetric eccentric long canal types; and an oblique position with a more dorsal location of the bar end on the less depressed side is used for asymmetric unbalanced and asymmetric combined types. In both bar position variants, the rigid subperiosteal fixation of the bar stabilizers to two ribs bilaterally is used. The results of treatment according to this modification were analysed in 24 patients with different variants of asymmetric PE.

Results. The proposed differentiated approaches to performing the Nuss procedure made it possible to obtain excellent and good cosmetic and functional results. There were three postoperative complications: one case of delayed pneumothorax and two cases of asymmetric manubriocostal pectus carinatum: one case after treatment of an asymmetric unbalanced PE (Park IIB) type and one – after correction of an asymmetric combined (Park IIC) type. Both patients with pectus carinatum underwent non-surgical treatment using an individually tailored dynamic compression brace system with excellent cosmetic and functional outcomes.

Conclusions. The several-point traction of the anterior chest wall allows to shape its physiological form in most cases; the rigid bar fixation according to the proposed schemes ensures the retention of the chest wall shape. In the vast majority of cases, the placement of one corrective bar is sufficient. For the asymmetric combined (Park IIC) type correction, the implantation of two corrective bars or the «sandwich technique» is indicated if the defect is significant. In case of postoperative pectus carinatum, successful non-surgical treatment using an individually tailored dynamic compression brace system is possible.

Keywords: Nuss procedure, asymmetric pectus excavatum, sternum elevation.

Тактика хірургічного лікування асиметричних форм лійкоподібної деформації грудної клітки в дітей

В. Р. Заремба¹, О. А. Данилов²

¹КНП «Житомирська обласна дитяча клінічна лікарня» Житомирської обласної ради, Україна

²Національний університет охорони здоров'я України імені П. Л. Шупика, м. Київ

Мета – поліпшити результати лікування пацієнтів із асиметричною формою лійкоподібної деформації грудної клітки (ЛДГК) шляхом розроблення та впровадження власної диференційованої модифікації операції за Nuss для корекції різних варіантів цієї деформації; проаналізувати результати лікування.

Оригінальні дослідження. Торакальна хірургія

Матеріали та методи. Описано оригінальну модифікацію операції Nuss для корекції таких типів деформації: асиметричного ексцентричного локального типу (IIA1 за Park); асиметричного ексцентричного широкого плаского типу (IIA2 за Park); асиметричного ексцентричного довгого глибокого типу (Grand Canyon, IIA3 за Park); асиметричного незбалансованого типу (IIB за Park); асиметричного комбінованого типу (IIC за Park). Суть запропонованої методики полягає в тому, що на початку операції проводиться поступове витягнення передньої грудної стінки в положення, максимально наближене до фізіологічного за дві й більше тракційні лігатури, накладені на грудину та ребра. У подальшому за асиметричного ексцентричного локального, асиметричного ексцентричного широкого плаского, асиметричного ексцентричного довгого глибокого типів ЛДГК використовується горизонтальне розташування фіксуючої пластини, а за асиметричного незбалансованого та асиметричного комбінованого типів – косе її положення з дорсальнішим розташуванням кінця пластини на менш запалому боці. В обох варіантах розташування пластини застосовується жорстка субокістна фіксація стабілізаторів пластини до двох ребер з обох боків. Проаналізовано результати лікування за цією модифікацією 24 пацієнтів із різними варіантами асиметричної ЛДГК.

Результати. Запропоновані диференційовані підходи до виконання операції Nuss дали змогу отримати відмінні й добрі косметичні та функціональні результати. Спостерігалися три післяопераційні ускладнення: один відстрочений пневмоторакс та два асиметричні кілеподібні деформації за манубріокостальним типом: один випадок – після лікування асиметричної незбалансованої форми деформації (IIB за Park) та один – після лікування асиметричного комбінованого типу (IIC за Park). Обидва пацієнти з кілеподібними деформаціями проліковані консервативно з використанням індивідуальної динамічної компресійної брейс-системи з відмінними косметичними та функціональними результатами.

Висновки. Кількочасова тракція передньої грудної стінки дає змогу сформувати в більшості випадків її фізіологічну форму; жорстка фіксація пластини за запропонованими схемами забезпечує збереження форми грудної стінки. В абсолютній більшості випадків достатньо встановити одну коригувальну пластину. Для корекції асиметричного комбінованого типу (IIC за Park) за значної поширеності рекомендована імплантація двох коригувальних пластин або використання «сандвіч-техніки». За формування післяопераційної кілеподібної деформації можливе успішне консервативне лікування в індивідуальній динамічній компресійній брейс-системі.

Дослідження виконано відповідно до принципів Гельсінської декларації. Протокол дослідження ухвалено Локальним етичним комітетом усіх зазначених у роботі установ. На проведення досліджень отримано інформовану згоду батьків дітей.

Автори заявляють про відсутність конфлікту інтересів.

Ключові слова: операція за Nuss, асиметрична лійкоподібна деформація грудної клітки, елевація груднини.

Introduction

Pectus excavatum (PE) is a fairly common malformation of the chest wall. The disease incidence is from 0.1 to 0.8 per 100 children and is a manifestation of connective tissue dysplasia. PE is characterized by functional and organic disorders of the cardiovascular and respiratory systems, namely: restrictive ventilatory insufficiency, frequent respiratory infections, cardiac compression signs, decreased exercise tolerance, and physical developmental delay [1–7]. In addition to organic and functional disorders, this malformation is significantly associated with frequent psychological disturbances, including problems in relations with the opposite sex, social adaptation deterioration, decreased socialization level, and in some cases it can lead to suicide [8,9]. Given the above reasons, the indications for the PE treatment are not only medical, associated with the cardiorespiratory and musculoskeletal system disorders, but also cosmetic and psychological ones.

In the 21st century, the PE treatment gold standard is the Nuss procedure. This operation and its modifications are widely used because of their low surgical injury, relative simplicity and short operation time, and good cosmetic and functional outcomes [2,3,10–19]. However, the treatment outcomes of patients with asymmetric pectus excavatum (APE) are not always perfect – often there is a residual deformity or pectus carinatum, as well as a

high incidence of postoperative complications, related re-operations, and chronic chest pain [6,7,16,18–24].

Objective. To improve the outcomes in patients with asymmetric PE by developing and implementing our own differentiated modified Nuss procedure to correct different variants of this deformity; to analyse the treatment outcomes.

Compliance with bioethical norms. The study was carried out in accordance with the principles of the Declaration of Helsinki. The study protocol was approved by the Ethics Commission of the Municipal Non-profit Institution Zhytomyr Regional Children's Clinical Hospital of Zhytomyr Regional Council, Ukraine.

Materials and methods

During the period from 2018 to 2020, the corrective operations for pectus excavatum according to the original modified Nuss procedure were performed in 76 patients. Among operated patients, asymmetric PE was diagnosed in 24 cases (31.6%). To assess the type, shape, degree and other characteristics of the deformity, we used the morphological classification of pectus excavatum proposed by H. J. Park. The distribution of patients is shown in Table 1.

Spirography, chest X-ray with determination of the deformity degree by Gizycka methods were used among the methods of examination. Native spiral computed tomog-

Table 1

Distribution of patients according to the Park classification

Deformity type according to Park	Quantity	Percent	Degree II	Average age of patients with deformity	Percent	Degree III	Average age of patients with deformity	Percent
IIA1 according to Park	7	29.2	3	13.0±0.47 (12.4, 13.6)	42.9	4	13.3±2.16 (10.7, 15.8)	57.1
IIA2 according to Park	3	12.5	3	15.7±0.72 (14.7, 16.7)	100.0	0	–	0.0
IIA3 according to Park	4	16.7	0	–	0.0	4	15.3±0.42 (14.7, 15.8)	100.0
IIB according to Park	6	25.0	4	11.8±0.2 (11.5, 12.0)	66.7	2	14.0±0.7 (13.0, 15.0)	33.3
IIC according to Park	4	16.7	4	12.8±0.7 (11.9, 13.6)	100.0	0	–	0.0
Total	24	100	14	13.1±1.8 (11.5, 16.7)	58.3	10	14.2±3.1 (10.7, 15.8)	41.7

Note: IIA1 according to Park – asymmetric eccentric focal type; Park IIA2 – asymmetric eccentric broad-flat type; IIA3 or the Grand Canyon type Park – asymmetric eccentric long canal type; Park IIB – asymmetric unbalanced type; Park IIC – asymmetric combined type.

raphy of the thoracic organs was performed to determine the degree of mediastinal displacement, indices of asymmetry, unbalance, eccentricity, and the Haller index.

An original modification of the Nuss procedure and its options for the treatment of various anatomical variants of APE were developed. The first stage of surgical intervention consisted of the application of ligatures (2–4) to the lower third of the sternum and adjacent ribs followed by gradual traction for 10–15 minutes until the anterior chest wall was positioned in the moderate hypercorrection. Recently, instead of a ligature, we have used a single-prong Volkmann retractor. The traction points were chosen at the greatest depression sites of the chest wall. The number of such points depends on the anatomical deformity variant, the chest wall rigidity and the thoracic cage size. The chest wall traction was performed by gradually tightening the stretching screw.

As a rule, bilateral three-centimetre transverse skin incisions at the level of the fifth intercostal space, anteriorly from the midaxillary line, with subperiosteal mobilization of the 5th and 6th ribs were made. The next step was tunnelling under the greater pectoral muscles and inserting an optical port on the right into the 6th or 4th intercostal space on the anterior axillary line. A working port was introduced through the right main access and a tunnel under the right greater pectoral muscle to the point of the bar entry into the pleural cavity. A 5-mm endoscopic dissector was inserted through the working port and the retrosternal tunnelling was performed. The next step was to introduce a guideband and a bar. After rotation of the bar, a bilateral rigid subperiosteal fixation of the bar stabilizers to two mobilized ribs was performed with a 5-mm lavsan band. This bar fixation technique transforms the construction into a monolithic metal arched structure with fixed

ends, which reduces the bar width and the pain syndrome severity in the points of bar entry into the pleural cavity, as well as levels out the rib deformation in these points.

The main difference in our approach to APE correction is traction of the anterior chest wall in its most concave areas, elevating the anterior chest wall to the position of hypercorrection first, after which a corrective bar with tightening of its ends (stabilizers) is introduced and fixed according to the deformity type. A prerequisite of this approach is a clear marking of the operating field, especially the points of bar entry into the pleural cavity.

Variants of the original technique

The explanations of symbols are shown in Figure 1.

1. To correct **the asymmetric eccentric focal type (IIA1 according to Park)**, the traction points were applied at the area of the corpus sterni transition into the xiphoid process along the edge, which is the closest to the deformity, and at the part of the rib, which is the closest to the deepest point of the deformity. The points of bar entry into the pleural cavity were planned along the edge of the deformity as in the conventional Nuss procedure. The bar was positioned horizontally (Fig. 2).

2. To correct **the asymmetric eccentric broad-flat type (IIA2 according to Park)**, two traction points were used. The first one was along the lower border of the corpus sterni and along its edge, closer to the depression, and the second one was in the area of the rib part closest to the deepest point of deformity. The points of bar entry into the pleural cavity were projected according to the deformity; the correction was made using two bars. The sternal traction was performed until significant hypercorrection position. This allowed the upper bar to be freely introduced after the lower one was inserted and rotated. The

Оригінальні дослідження. Торакальна хірургія

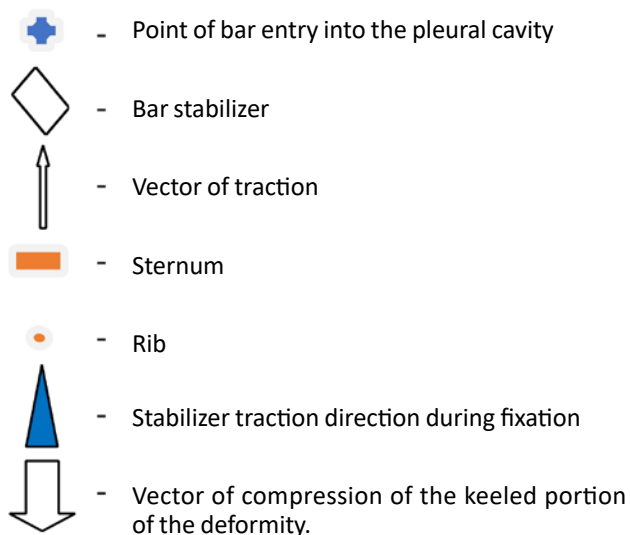


Fig. 1. Symbols

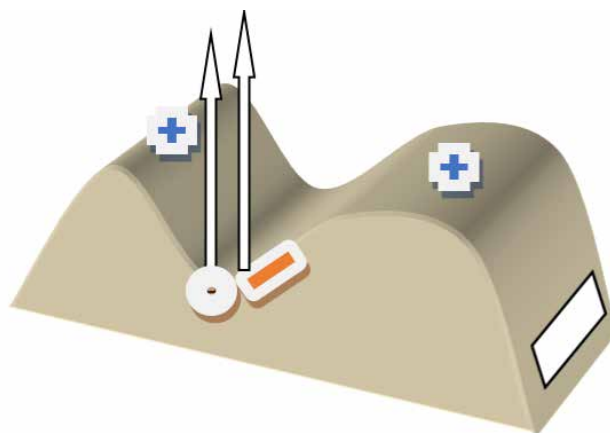


Fig. 2. Scheme of asymmetric eccentric focal (IIA according to Park) type correction

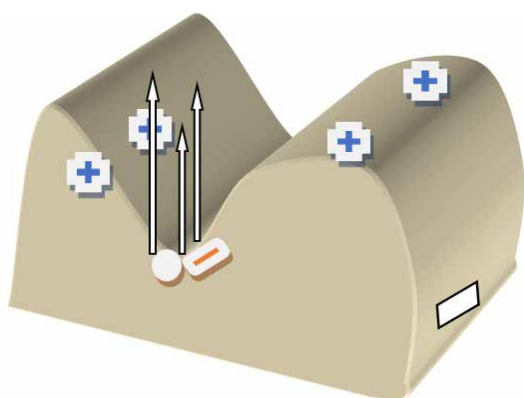


Fig. 4. Scheme of asymmetric eccentric long canal (the Grand Canyon type or IIA3 according to Park) type correction

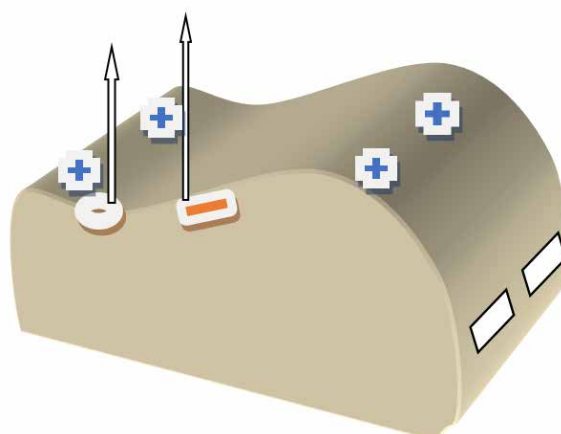


Fig. 3. Scheme of asymmetric eccentric broad-flat (IIA2 according to Park) type correction

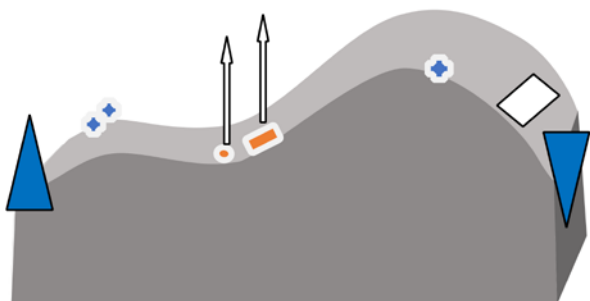


Fig. 5. Scheme of asymmetric unbalanced (II B according to Park) type correction

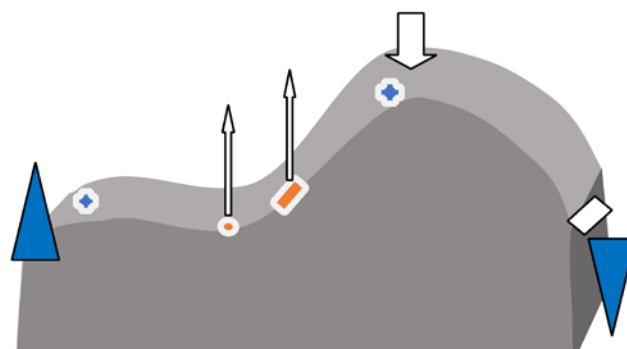


Fig. 6. Scheme of asymmetric combined (II C according to Park) type correction

upper bar was placed in accordance with the points of bar entry into the pleural cavity in the third intercostal space using the Pilegaard technique, or this bar was placed with one nonremovable stabilizer. After positioning both bars, the sternum was reversed from the hypercorrection position to the physiological one. Then we fixed them to the ribs (Fig. 3).

3. Surgical treatment of **the asymmetric eccentric long canal type (the Grand Canyon type or IIA3 according to**

Park). Three traction points were used at the lower edge level of corpus sterni: the middle of the sternum, the edge of the sternum close to the deformity, and the rib slightly laterally to the deepest point of the deformity. Two bars were used. Optionally, the fixation was provided using simultaneously lavsan band and steel ligature No.7 USP. The sequence of insertion and bar fixation were similar to those performed for the correction of asymmetric eccentric broad-flat (IIA2 according to Park) type (Fig. 4).

4. Correction of **asymmetric unbalanced (IIB according to Park) type**. Two traction points were made at the level of the lower edge of the sternal body along its edge closer to the deformity and 2–3 cm lateral to this point on the rib. The latter was given special attention during traction. In this operation variant, there was used an oblique course of the corrective bar with the lower bar side placed on the concave side. It is crucial to place the bar accurately, which is as follows: from the convex side of the chest, the bar enters into the pleural cavity along the edge of the deformity, and on the concave side, it is introduced in the middle between the anterior axillary and medioclavicular lines. In this type of deformity, it is important that the stabilizers are properly fixed to the ribs, namely:

a) on the concave side, the fixation points are pulled as far forward as possible, elevating the chest wall to the physiological position;

b) on the concave side, three points of subperiosteal fixation to the ribs are used: at both ends of the stabilizer and the bar ends;

c) the bar should be placed so that the removable stabilizer is positioned on the concave chest side;

d) a combination of suture materials, both steel ligature and lavsan band on the concave side, should be preferred.

The oblique bar course allows 3–4 ribs of the concave side of the chest (almost the entire concave surface) to lean on the bar (Fig. 5).

5. **The asymmetric combined type (IIC according to Park)** was corrected using one bar. First, traction ligatures were applied at the level of the lower edge of the corpus sterni and 2–3 cm laterally to the rib on the funnel-shaped deformity side. The funnel-shaped part of the deformity was elevated into a position close to the contralateral side. The bar position was horizontal or oblique (usually oblique). It was inserted so that the bar entry point into the pleural cavity from the keeled side was somewhat medial to the top of the keeled portion of the deformity, and on the funnel-shaped side – along the border of the funnel-shaped deformity.

The rules for the bar fixation to the ribs were as follows:

a) on the funnel-shaped side, the fixation points were pulled as far forward as possible, elevating the chest wall to the physiological position;

b) there were three points of subperiosteal fixation bilaterally: at both ends of the stabilizer and the bar ends;

c) a bar with two removable stabilizers was used;

d) a combination of suture materials, both steel ligature and lavsan band, was preferred on both sides;

e) the bar was fixed to the ribs on the funnel-shaped side first, trying to fasten the stabilizer as ventrally as possible, after which the bar was fixed from the keeled side by pressing on the top of the keeled portion of the deformity until it was corrected, but the stabilizer should be fixed as dorsally as possible.

We consider it appropriate to introduce two bars with a significant upper-lower size of the keeled portion in the IIC type according to Park (Fig. 6).

Results

An analysis of the surgical treatment results in the patients with APE using the modified Nuss procedure showed that 23 out of 24 patients (95.8%) had good and excellent surgical treatment outcomes. The majority of patients were males (62.5%). It was found a tendency for the third-stage deformity percentage to increase with the child's age (from 27.2% at the age of 10–13 years to 38.4% at the age of 14–18 years). Two corrective bars were used in all patients with asymmetric eccentric long canal (the Grand Canyon type or Park IIA3) type (4 cases) and asymmetric eccentric broad-flat (Park IIA2) type (3 cases) (in 29.17% of all patients with APE). The correction using one bar was provided in the other 17 patients (70.83%).

The duration of the operation ranged from 55 to 100 minutes when one fixation bar was placed (on average – 78 minutes) and from 100 to 130 minutes (on average – 108 minutes) with two fixation bars placed. The intraoperative blood loss was less than 30 ml in all cases.

There were three postoperative complications (12.5%) registered: delayed simple right-sided pneumothorax (diagnosed 1.5 days post surgery) in one case and two cases of recurrence in the form of pectus carinatum in 3 and 6 months post surgery for an asymmetric unbalanced (Park IIB) type and for an asymmetric combined (Park IIC) type.

The length of hospital stay post surgery was 3–7 days (on average 4.2 days). In 23 cases (95.8%), good and excellent treatment outcomes were noted. There were no cases of bar displacement or penetration through the anterior chest wall. The examples of treatment outcomes are shown in Figures 7–10.

Discussion

Most authors believe that the Nuss procedure is effective in symmetrical PE. Moreover, it is possible to limit the placement of a single bar to complete deformity correction [2,3,6,12,14,15,18]. It has been reported the minimum number of intra- and postoperative complications in these cases [2,3,6,12,14]. However, asymmetric PEs pose considerable difficulties when performing PE correction according to Nuss [6,13,22–24]. Taking this into account, a placement of two or more bars, including bridge structures, have been suggested by a number of authors [10,16,23,25]. This approach is more often accompanied by intra- and postoperative complications, decreased respiratory capacity because of reduced chest wall mobility [6,22–24]. There are very few studies on the methods and results of the APE treatment. The Park's work [26] is of the greatest interest

Оригінальні дослідження. Торакальна хірургія

because of the approaches used and the results obtained. In particular, H. J. Park has suggested the use of an original approach – MM–MT TERCOM (multiple-momentum based multitarget «Terrain Contour Matching System»). In this approach, the first step is to establish the deformity portions that need to be corrected surgically. After establishing the goals of correction, the bar contour, which would be anti-congruent to the deformation, is carried out for such correction. To achieve this goal, H. J. Park recommends the «deformity contour matching», which is essentially a mirror-image fitting of the bar curvature to the chest wall curvature. Techniques have been described for introducing bridge structures consisting of two fixation bars, in particular, the «sandwich technique», to correct the asymmetric combined PE (Park IIC) type [16,23,25,26]. In addition, there have been anecdotal studies on the use of several fixation bars to correct the Grand Canyon deformity type and extended deformity variants [10,11]. Thus, no systematic approach to surgical treatment of different asymmetric PE variants has been proposed so far. In our opinion, the main cause of complications is the lack of proper attention to the deformity type and nature. H. J. Park has identified the main types of asymmetric pectus excavatum. The classification was developed taking into account the position of the sternum and the changes in the shape of ribs and costal arches [27]. The most common cause of intraoperative complications is the narrow space or its absence between the anterior mediastinal organs and the anterior chest wall, as well as the mediastinal displacement, since this significantly impairs the safety of manipulations in the retrosternal space [6,10,11,19,22,24]. The anterior chest wall elevation, performed in the operation debut in different ways, can reduce the risk of complications [10,11,17,19]. However, the authors do not take into account the location of traction points depending on the nature of the deformity and, therefore, do not achieve the physiological position of the anterior chest wall before the placement and fixation of the bars. On the contrary, a differentiated choice of traction points allows optimally placing the corrective bars, taking into account the localization of the deformity epicentre and its anatomical variant, and achieving good results. Under this approach, it is enough to install one fixation bar in most cases, and the oblique bar position is often chosen.

Conclusions

The proposed modified Nuss procedure with several-point traction of the anterior chest wall in the operation debut allows to form its physiological shape in most cases, and rigid fixation of the bar stabilizers according to the proposed schemes reliably maintains the achieved shape of the chest wall. In almost all cases, good to excellent correction results have been achieved. In the vast

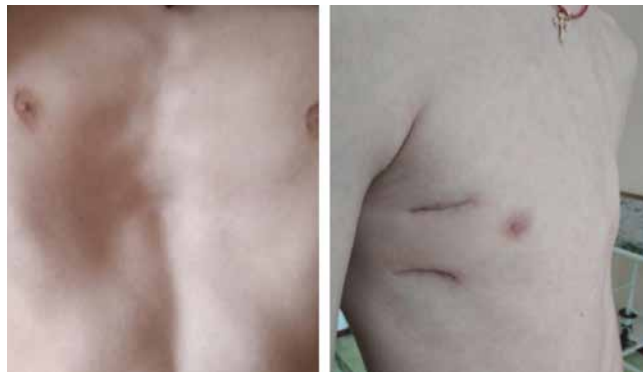

Fig. 7. Case of asymmetric eccentric broad-flat (IIA2 according to Park) type correction

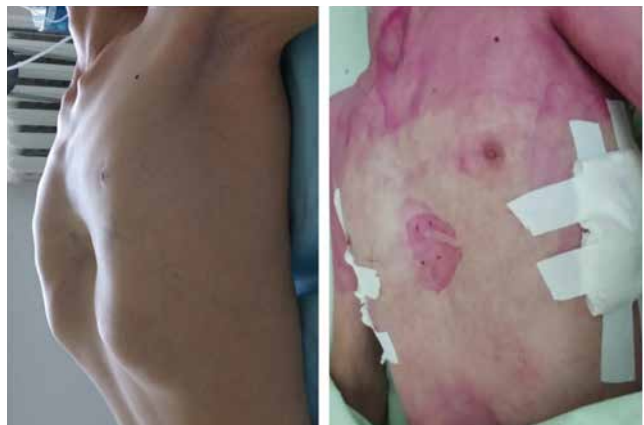

Fig. 8. Case of asymmetric eccentric focal (IIA according to Park) type correction

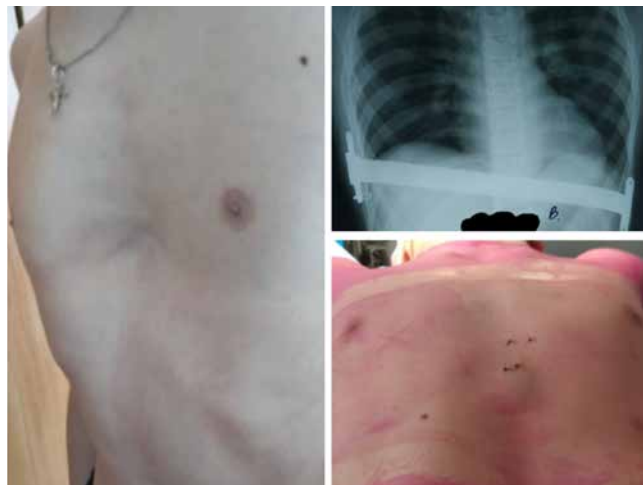

Fig. 9. Case of asymmetric unbalanced (II B according to Park) type correction

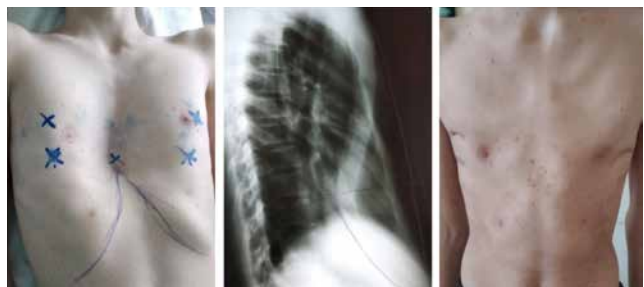

Fig. 10. Case of asymmetric eccentric long canal (the Grand Canyon type or IIA3 according to Park) type correction

majority of cases, the placement of one corrective bar is sufficient. When correcting the asymmetric combined (IIC according to Park) type, consideration must be given to the height of the keeled portion of the deformity and, with a significant protruding part in height, it is recommended to use two corrective bars or use the «sandwich technique» to prevent the postoperative pectus carinatum. In case of postoperative pectus carinatum, successful non-surgical treatment using an individually tailored dynamic compression brace system is possible.

Conflict of interest statement. The authors declare no conflict of interest.

Financing. The work was done at the expense of the authors.

References/Література

- Albokrinov AA, Myhal II, Fesenko UA, Kuzyk AS, Dvorakevych AO. (2016). Chastota vynyknennia khronichnoho bolii pislia korektsii liikopodibnoi deformatsii hruudnoi klitky za Nuss u ditei. Paediatric Surgery. Ukraine. 1–2 (50–51). [Альбокрінов АА, Мигаль ІІ, Фесенко УА, Кузик АС, Дворакевич АО. (2016). Частота виникнення хронічного болю після корекції лікоподібної деформації грудної клітки за Nuss у дітей. Хірургія дитячого віку. Україна. 1–2 (50–51)].
- Colombani P. (2010). Pectus repair at J. Hospital. Pediatric Chest Wall Deformities Concepts and Conformities; Adobe connect.
- Haecker FM, Mayr J. (2006). The vacuum bell for treatment of pectus excavatum: an alternative to surgical correction. Eur J Cardiothorac Surg. 29:557–61.
- Hebra A, Kelly RE, Ferro MM, Yüksel M, Campos JRM, Nuss D. (2018). Life-threatening complications and mortality of minimally invasive pectus surgery. J Pediatr Surg Apr. 53 (4):728–732.
- Holcomb G. (2010). Pectus excavatum the KC experience. Pediatric Chest Wall Deformities Concepts and Conformities. Adobe connect.
- de Campos JRM, Tedde ML. (2016) Management of deep pectus excavatum (DPE). Ann Cardiothorac Surg. 5 (5):476–484.
- Kelly RE Jr, Lawson ML, Paidas CN, Hruban RH. (2005). Pectus excavatum in a 112-year autopsy series: anatomic findings and the effect on survival. J Pediatr Surg. 40: 1275–8.
- Kelly RE Jr, Shamberger RC, Mellins RB, Mitchell KK, Lawson ML, Oldham K, et al. (2007). Prospective multicenter study of surgical correction of pectus excavatum: design, perioperative complications, pain, and baseline pulmonary function facilitated by internet-based data collection. J Am Coll Surg. 205:205–16.
- Kryvchenia DYu., Prytula VP, Kharsika SM, Zavodii VH. (2014). Liikopodibna deformatsiia hruudnoi klitky. Poperechne sichennia perednoi plastynky hruudnyu yak dopovnennia do miniinvazyvnoi korektsii za metodom Nussa. Arkhiv klinichnoi medytsyny. 2:64–65. [Кривченя ДЮ, Притула СМ, Харсіка ВГ, Заводій ВГ. (2014). Лікоподібна деформація грудної клітки. Поперечне сінчення передньої пластинки груднини як доповнення до мініінвазивної корекції за методом Нусса. Архів клінічної медицини. 2:64–65].
- Kubiak R, Habelt S, Hammer J, Hacker FM, Mayr J, Bielek J. (2007). Pulmonary function following completion of Minimally Invasive Repair for Pectus Excavatum (MIRPE). Eur J Pediatr Surg. 17:255–60.
- Dore M, Junco PT. (2018). Nuss Procedure for a Patient with Negative Haller Index. European Journal of Pediatric Surgery Reports. 6 (1):18–22.
- Nuss D. (2010). Indication of pectus repair. Pediatric Chest Wall Deformities Concepts and Conformities. Adobe connect.
- Nuss D, Kelly RE. (2014). The minimally invasive repair of pectus excavatum. Oper Tech Thorac Cardiovasc Surg. 19 (03):324–347.
- Ovechkin AM (2016). Khronicheskyi posleoperatsyonnyi bolevoi syndrom – podvodnyi kamen srovennoyi khirurgii. Regionarnaya anesteziya i lechenie ostroy boli. 10 (1):5–18. [Овечкин АМ. (2016). Хронический послеоперационный болевой синдром – подводный камень современной хирургии. Регионарная анестезия и лечение острой боли. 10 (1):5–18].
- Park HJ. (2010, Feb). Minimally invasive repair of pectus excavatum: A novel morphology-tailored, patient-specific approach. The Journal of Thoracic and Cardiovascular Surgery. 139 (2):379–386.
- Park HJ. (2007, Jan). Technical innovations in the minimally invasive approach for treating pectus excavatum: a paradigm shift through six years' experience with 630 patients. Innovations (Phila). 2 (1):25–8.
- Park HJ, Chung WJ, Lee IS. (2008). Mechanism of bar displacement and corresponding bar fixation techniques in minimally invasive repair of pectus excavatum. J. Pediatr. Surg. 43 (1):74–8.
- Park HJ, Kim KS, Moon YK, Lee S. (2015). The bridge technique for pectus bar fixation: a method to make the bar un-rotatable. J Pediatr Surg. 50 (08):1320–1322.
- Park HJ, Sung SW, Park JK. (2012). How early can we repair pectus excavatum: the earlier the better? Eur. J. Cardiothorac. Surg. 42 (4): 667–72.
- Pilegaard HK, Licht PB. (2008). Early results following the Nuss operation for pectus excavatum—a single-institution experience of 383 patients. Interact. Cardiovasc. Thorac. Surg. 7 (1): 54–7.
- Puri V. (2015). Making the Nuss repair safer: use of a vacuum bell device. J Thorac Cardiovasc Surg. 150 (05):1374–1375.
- Razumovskiy AIu, Alkhasov AB, Mytupov ZB, Dalakian DN, Saveleva MS. (2017). Analiz peryoperatsyonnykh oslozhneniy pry korektsii voronkoobraznoi deformatsii hruudnoi klitky po modyfytsirovannoi metodyke Nassa. Detskaia khirurgiia. 21 (5):251–257. [Разумовский АЮ, Алхасов АБ, Митупов ЗБ, Далакян ДН, Савельева МС. (2017). Анализ периоперационных осложнений при коррекции воронкообразной деформации грудной клетки по модифицированной методике Насса. Детская хирургия. 21 (5):251–257].
- Kelly RE, Lombardo JrML. (2017). Psychologic Effects, Body Image, and Pectus Excavatum and Carinatum. Saxena Amulya K. Chest Wall Deformities, Department of Pediatric Surgical University Medical Centre, Münster, Germany:169–175.
- Schaarschmidt K. (2011). Modified Nuss «Berlin Technique». J. Pediatr. 40 (9):1407–10.
- Steinmann C, Krille St, Mueller A, et al. (2011). Pectus excavatum and pectus carinatum patients suffer from lower quality of life and impaired body image: a control group comparison of psychological characteristics prior to surgical correction. Eur J Cardiothorac Surg. 40 (5):1138–1145. doi: 10.1016/j. ejts.2011.02.019.
- Yoshida K, Kashimura T, Kikuchi Y, Nakazawa H. (2019, Jul-Sep). Successful management for repeated bar displacements after Nuss method by two bars connected by a stabilizer. Ann Thorac Med. 14 (3):216–219.
- Zallen GS, Glick PL. (2004). Miniature access pectus excavatum repair: Lessons we have learned. J. Pediatr. Surg. 39:685–9.

Відомості про авторів:

Заремба Віталій Ростиславович – лікар-хірург дитячий вищої кваліфікаційної категорії КНП «Житомирська обласна дитяча клінічна лікарня» Житомирської ОР. Адреса: Житомирський район, с. Станішівка, шосе Сквирське, 6. <https://orcid.org/0000-0003-4231-4342>.

Данилов Олександр Андрійович – д.мед.н., проф. каф. дитячої хірургії НУОЗ України імені П. Л. Шупика. Адреса: м. Київ, вул. Дорогожицька, 9. <https://orcid.org/0000-0002-4605-7032>.

Стаття надійшла до редакції 27.11.2021 р., прийнята до друку 6.03.2022 р.