

I.A. Lurin¹, E.M. Khoroshun^{2,3}, V.V. Nehoduiko^{2,3}, V.V. Makarov^{2,3}, Yu.V. Bunin²,
R.V. Salyutin⁴, S.V. Tertyshnyi⁵

Videothoroscopic removal of a foreign body (arrow-shaped element) of gunshot origin from the vertebral body, using radiation and magnetic technologies

¹SI «Scientific and Practical Center of Preventive and Clinical Medicine» of the State Administration of Affairs, Kyiv, Ukraine

²Military Medical Clinical Center of the Northern Region Command of Medical Forces of the Armed Forces of Ukraine, Kharkiv

³Kharkiv National Medical University, Ukraine

⁴Shalimov National Institute of Surgery and Transplantology of the NAMS of Ukraine, Kyiv

⁵Military Medical Clinical Center of the Southern Region Command of Medical Forces of the Armed Forces of Ukraine, Odesa

Paediatric Surgery(Ukraine).2022.4(77):96-100; doi 10.15574/PS.2022.77.96

For citation: Lurin IA, Khoroshun EM, Nehoduiko VV, Makarov VV, Bunin YuV, Salyutin RV, Tertyshnyi SV. Videothoroscopic removal of a foreign body (arrow-shaped element) of gunshot origin from the vertebral body, using radiation and magnetic technologies. Paediatric Surgery (Ukraine). 4 : 96-100. doi: 10.15574/PS.2022.77.96.

Gunshot wounds to the chest have always occupied a special place among the entire set of gunshot wounds on the human body. Today, the one of the important challenges before the Navy of the Armed Forces of Ukraine, – not only to restore the damaged anatomical structures of the chest, but also to create optimal conditions for the restoration of the functional component. This will make possible to reduce the treatment period of a wounded serviceman and return him to the formation (or to the occupied position) as soon as possible.

The use of minimally invasive methods (videothoracoscopy, radiation control and magnetic technologies) during the treatment of a wounded person with a penetrating gunshot wound of the chest is the key in the surgeon's hands whose task is to save life and eliminate the defect (formed as a result of the wound). This approach is not only an example of highly specialised surgical care for the wounded in the navy, but also demonstrates the high quality of the proposed care scheme.

Purpose – practically implement new organisational, tactical and professional approaches to the treatment of gunshot wounds to the thorax using a clinical case study.

It is presented the **clinical case** of *wounded man Sh.*, 35 years old, with a gunshot fragmentation blind wound of the posterior surface of the thorax, gunshot fracture of the Th7 vertebral body on the background of a foreign body (metal arrowhead).

In the current world literature, there are many options for surgical tactics for the treatment of wounded patients with penetrating gunshot wounds to the chest. However, our clinical case draws attention to the high relevance of applying and combining minimally invasive techniques (video-othoracoscopy, radiation control and magnetic technology). This makes it possible to reduce the time (or duration) of surgical intervention, perform an «extended» revision of the pleural cavity, examine and assess the condition of the wound canal, remove a foreign body (shrapnel, bullets, arrowhead component), compensate for respiratory failure phenomena as quickly as possible and restore the integrity and function of the thoracic cells.

The research was carried out in accordance with the principles of the Helsinki Declaration. The informed consent of the patient was obtained for conducting the studies.

No conflict of interests was declared by the authors.

Keywords: gunshot wounds of the chest, video thoracoscopy, radiation control, magnetic technologies.

Відеоторакоскопічне видалення інородного тіла (стріловидного елемента) вогнепального походження з тіла хребця з використанням променевої та магнітної технологій

I.A. Лурін¹, Е.М. Хорошун^{2,3}, В.В. Негодуйко^{2,3}, В.В. Макаров^{2,3}, Ю.В. Бунін², Р.В. Салютін⁴, С.В. Тертишний⁵

¹ДУ «Науково-практичний центр профілактичної та клінічної медицини» Державного управління справами, м. Київ, Україна

²Військово-медичний клінічний центр Північного регіону Командування медичної служби Збройних Сил України, м. Харків

³Харківський національний медичний університет, Україна

⁴Національний інститут хірургії та трансплантології імені Шалимова НАН України, м. Київ

⁵Військово-медичний клінічний центр Південного регіону Командування медичної служби Збройних Сил України, м. Одеса

Вогнепальні поранення грудей посідають особливе місце серед усієї сукупності вогнепальних поранень на тілі людини. На сьогодні одне з важливих завдань, що стоять перед Військово-Морським Флотом Збройних Сил України, – не тільки відновити пошкоджені анатомічні структури грудної клітки, але й створити оптимальні умови для відновлення функціональності. Це дасть змогу скоротити терміни лікування пораненого і повернути його в стрій (або на обійману посаду) у найкоротші терміни.

Використання мініінвазивних методів (відеоторакоскопія, променевий контроль і магнітні технології) під час лікування пораненого з проникаючим вогнепальним пораненням грудної клітки є ключовим у руках хірурга, завдання якого полягає у збереженні життя та ліквідації дефекту, що утворився внаслідок поранення. Такий підхід є не тільки прикладом вузькоспеціалізованої хірургічної допомоги пораненим на флоті, аде й демонструє високу якість запропонованої схеми надання медичної допомоги.

Мета – практичне впровадження нових організаційно-тактичних і професійних підходів до лікування вогнепальних поранень грудної клітки на прикладі клінічного випадку.

Наведено **клінічний випадок пораненого Ш.**, 35 років, із вогнепальним осколковим сліпим пораненням задньої поверхні грудної клітки, вогнепальним переломом тіла Th7 хребця на тлі стороннього тіла (металевий стрілоподібний елемент).

У сучасній світовій літературі існує безліч варіантів хірургічної тактики лікування поранених із проникаючими вогнепальними пораненнями грудей. Однак у нашому клінічному випадку звернуто увагу на високу актуальність застосування і поєднання мініінвазивних методів (відеоторакоскопія, променевий контроль і магнітні технології). Це дає змогу скоротити час (або термін) оперативного втручання, виконати «розширену» ревізію плевральної порожнини, оглянути й оцінити стан ранового каналу, видалити стороннє тіло (уламки, кулі, стрілоподібний компонент), якнайшвидше компенсувати явища дихальної недостатності та відновити цілісність і функцію клітин грудної клітки.

Дослідження виконано відповідно до принципів Гельсінської декларації. На проведення досліджень отримано інформовану згоду пацієнтів. Автори заявляють про відсутність конфлікту інтересів.

Ключові слова: вогнепальні поранення грудей, відеоторакоскопія, променевий контроль, магнітні технології.

Introduction

Today, trauma to the chest and organs of the chest cavity has acquired a new character and relevance.

This is caused by the enemy's use of high-energy weapons and weapons with new combined qualities. Knowledge of ballistic and other characteristics of modern weapons allows us to fully assess the specifics of damage to all anatomical structures of the chest.

Considering all the characteristics of the weapon used by the enemy (energy component of the striking object, shape and size, features of damaged tissues), it is possible, already at the initial stage, to have a clear idea about the size of the striking component, the deformation capacity depending on the density of the tissues through which it passes and the features of the damage.

The energy component of firearms is more damaging to bone tissue – the rib cage frame compared to soft tissue structures [1].

Wounds, like injuries of the chest, can be divided into penetrating and non-penetrating, a special part is occupied by penetrating wounds of the chest. In this clinical case the focus is on specifics of a penetrating wound of the chest, which in turn can be further divided de-

pending on the speed of the damaging components (high-speed and low-speed). Shells with a movement speed of the wound component up to 360 m/s are low-speed, in the case of a wound component of 650–700 m/s, it needs to talk about high-speed options. Classically, shells can develop this speed after the explosion. The difference between such speed and energy component characteristics determines the peculiarities of damage to the anatomical structures of the chest and possibility of changing the wound channel due to the heterogeneity of the anatomical components [8].

Among chest injuries, it is singled out on a special group of penetrating chest injuries. According to the quantitative indicator in statistical studies, there are fewer penetrating wounds than non-penetrating ones, but the severity of the wound process and the cascade of complications show a higher percentage of fatalities. The research in the United States indicates that chest injuries account for 9% of all deaths, of which 33% are penetrating chest injuries [5]. The main part of gunshot wounds consists of military personnel's wounds, the rest is caused by wounds of civilians and a high number of firearms among civilians [3,4,7]. Specialized trauma centers with appropriate tech-

Клінічний випадок

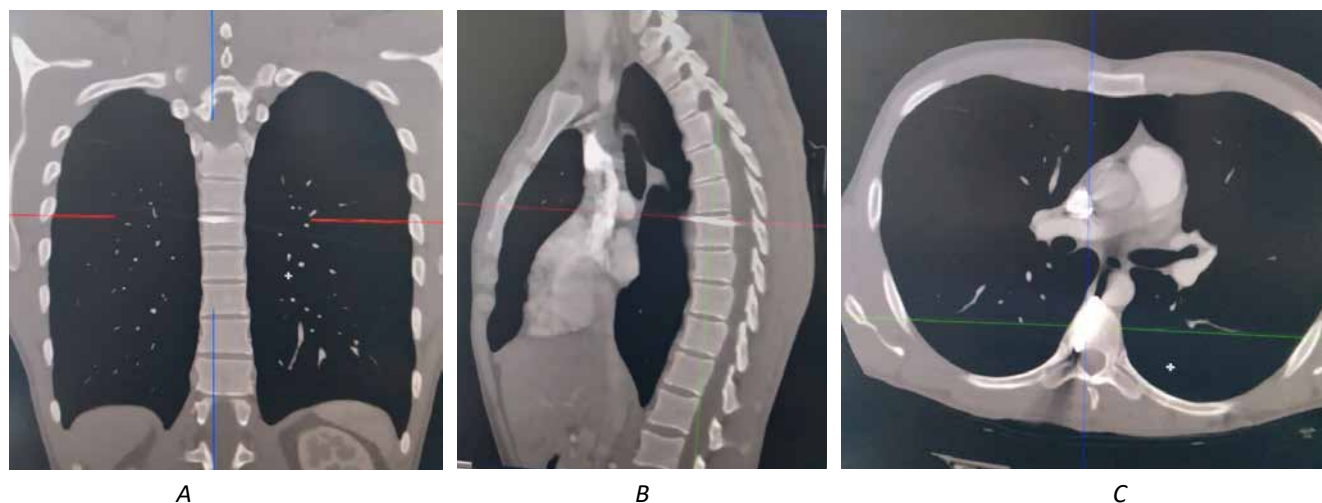


Fig. 1. Spiral computer tomography of chest organs: A – longitudinal; B – sagittal; C – lumbar. The presence of a foreign body (a metal arrow-shaped element) in the body of the 7th thoracic vertebra

nical support have been created around the world to solve such an urgent issue. Traumatology teams, working in these centers, provide surgical care according to the protocols of emergency care to the injured with damage to the chest [2]. Such specialization of the centers makes possible to offer fast and high-quality treatment of «specific» gunshot wounds of the chest.

In Ukraine gunshot wounds to the chest have gained new relevance is due to the use of new types of weapons. Therefore, the provision of surgical care to the wounded of this category is a special problem for the Navy of Ukraine.

Purpose of the study – practically implement new organisational, tactical and professional approaches to the treatment of gunshot wounds to the thorax using a clinical case study.

Clinical case

The clinical example we present is a wounded serviceman of the Armed Forces of Ukraine *Sh.*, 35 years old, injured during a mine explosion in the north of Ukraine in June 2022. The advanced surgical group provided the first medical care on the front line. They performed primary surgical treatment of the wound, administering antibiotic and tetanus prophylaxis. Two hours after the injury he was taken to the Military Medical Clinical Center of the Northern Region (MMCC NR), and after examination by a multidisciplinary team of surgeons he was hospitalized at the neurosurgery department.

The research was carried out in accordance with the principles of the Helsinki Declaration. The informed consent of the patient was obtained for conducting the studies.

Objectively: Condition is satisfactory. Body temperature is 36.5°C. The body structure is correct. Physical

development is average. Skin and visible mucous membranes are clean, normal color. Palpable lymph nodes are not enlarged, displaced. There is a clear lung percussion sound over the lungs, vesicular breathing, no wheezing. Pulse 88 per minute, rhythmic. The limits of the heart are within the age norm. Heart tones are clear, rhythmic. Blood pressure 120/70 mm Hg. The tongue is clean, moist. The abdomen participates in the act of breathing, is not distended, soft, palpable in all sections, painless. Peristaltic bowel sounds are normal. The kidneys are not palpable, tapping on the lumbar region is painless. The liver and spleen are not enlarged. Symptoms of peritoneal irritation are negative. Consciousness is clear (15 points on the Glasgow scale), Adequate. Pupils S=D, narrow. The face is symmetrical. Hearing is preserved. Active movements and sensitivity in the limbs are preserved. Urination is independent, controlled. There was no defecation during the observation period. Can walk independently. Locally: a wound with smooth edges, size 1.0×0.3 cm at the level of Th7 vertebra 3 cm lateral to the right of the midline.

On the spiral computed tomography (CT) of the thoracic organs: signs of a foreign body of metal density in the form of a rod with a diameter of about 3 mm, 40 mm long in the right part of the arch of the Th7 vertebra, which is included in the lateral masses of this vertebra on the right. The end part of the foreign body protrudes 2 mm in front of the vertebra body. No stenosis of the spinal canal was detected. There are no signs of pathological changes in the lungs and mediastinal organs (Fig. 1).

The operation on the wounded included: video-assisted thoracoscopy of the left pleural cavity, revision, osteotomy of the Th7 vertebra, removal of a foreign body (a metal arrow-shaped shell), sanitation and drainage of

the right pleural cavity according to Bülau under general anesthesia with one-lung intubation (left) and artificial lung ventilation (VLA). After treatment of the operative site under general anesthesia with one-lung intubation (left) and mechanical ventilation, a thoracoport for 10 mm oblique optics was installed in the 6th intercostal space along the front axillary line on the right. Working thoracopores are installed in the 7th intercostal space along the middle axillary line and in the 6th intercostal space along the posterior axillary line on the right. Revision of the right pleural cavity – subpleural hemorrhage is visualized in the projection of the Th7 vertebra. Additional navigation was performed with the help of the fluorographic X-ray general purpose mobile Carmex RK FP (Italy, 2021) system (Fig. 2).

The pleura is gradually dissected above Th7, the pleural dissection continues medially. The vena cava is diverted medially. The tip of a metal arrowhead is visualized directed medially to the vena cava and aorta. There are no data on active bleeding. The body of the vertebra is cleaned of soft tissues, coagulated. With the help of an arthroscopic shaver, the osteotomy of the Th7 body was performed strictly in the projection of the foreign body's position along the course of the wound canal (Fig. 3).

After complete extraction, the foreign body is removed from the body of the Th7 vertebra using a magnetic tool for endovideoscopic diagnosis and removal of metal ferromagnetic foreign bodies from the abdominal and pleural cavities and removed from the pleural cavity (Fig. 4).

Postoperative diagnosis: blind gunshot wound of the chest in the area of the Th7 vertebra with a fracture of its body and presence of a foreign body (a metal arrow-shaped element).

The uniqueness of this case is in the presence of an isolated gunshot injury to the vertebra located near the main mediastinal vessels, removal of a foreign body (sagittal element) using minimally invasive methods (videothoracoscopy, radiation control and magnetic technologies). It is not only a minimally invasive technique but also a bright addition to surgical mastery of thinking and practical implementation of modern technological capabilities of the MMCC of the North region in treatment of the wounded with gunshot wounds of the chest.

Discussion

Looking at the methodology proposed by the team of the authors, it should notes that the wounded has stayed in the hospital of the Medical Center of the North region for 12 days. There are no complications from the respiratory, cardiovascular and nervous systems. The wound

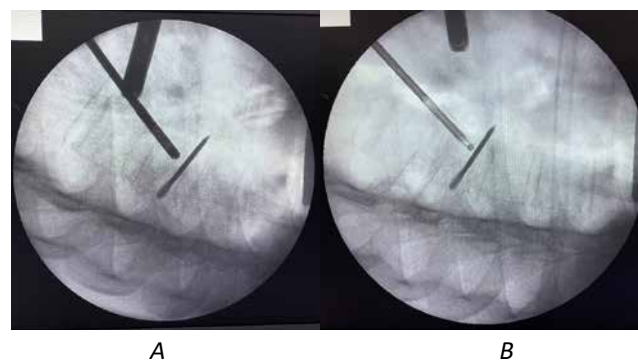


Fig. 2. Radio control of the video thoracoscopic tool navigation using fluorographic x-ray general purpose system of the mobile Carmex RK FP to the location of the metal arrow-shaped element

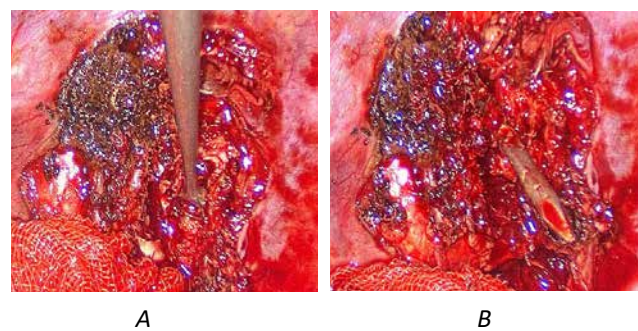


Fig. 3. Video thoracoscopic control of a foreign body removal (sagittal element): A – decortication of the vertebra with the help of an arthroscopic shaver; B – removal of the sagittal element from the bone tissue

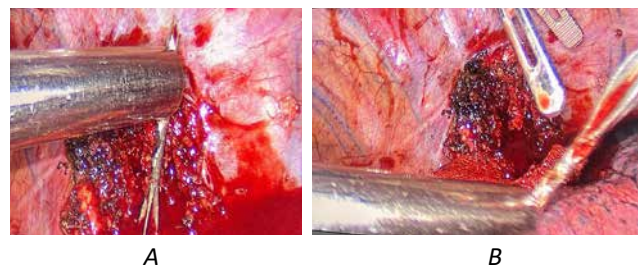


Fig. 4. Fixation and removal of a foreign body (arrow-shaped element) from the vertebra body: A – fixation and removal of a ferromagnetic metal arrow-shaped element using a magnetic tool for endovideoscopic diagnosis and removal of metal ferromagnetic foreign bodies from the abdominal and pleural cavities; B – interception of a sagittal element with a thoracoscopic tool for removal from the pleural cavity

healed with initial tension, after which the injured person was sent on a medical leave for 30 calendar days.

Thus, our clinical case confirms that chest injuries can have a high mortality rate and a high level of complications, but the use of minimally invasive technologies in combination with dynamic X-ray control and magnetic technologies improves treatment results. They also reduce the number of thoracotomies, increasing the survival rate. Focused X-ray and sonographic evaluation

Клінічний випадок

during the pre- and post-operative examination is the method of choice, especially in the wounded with a severe and unstable condition. In case of damage to the bone structures of the chest, stable ventilation and adequate anesthesia should be considered as an additional requirement, making it possible to apply minimally invasive methods with high quality.

Conclusions

A gunshot wound to the chest can be a life-threatening event because it is often accompanied by damage to the organs of the chest, leading to high mortality. The use of new imaging methods – CT examination, CT angiography, ultrasound of the chest in current conditions make it possible to apply minimally invasive technologies and develop alternative options for diagnosis and dynamic monitoring of gunshot wounds. The work of the multidisciplinary team in accordance with the developed guidelines made it possible to conduct a thorough assessment of the gunshot wound and apply an effective treatment strategy.

Clear subordination and implementation of medical aid protocols on the example of the MMCC of the North region has demonstrated a new approach to solution of such a difficult issue as a gunshot wound to the chest with a gunshot fracture of the body of the Th7 vertebra and presence of a foreign body (a metal arrow-shaped element).

Mobilization and coordination due to a high-quality and professional administrative resource, a unified view or strategic tactics of actions according to the protocols, demonstrate the readiness of the Armed Forces Navy to provide medical care according to world standards.

The authors have declared no potential conflict of interest with respect to the research, authorship, and/or publication of this article.

No conflict of interests was declared by the authors.

References/Література

- Boyd AD, Glassman LR. (1997). Lung injury. *Chest Surg Clin N Am.* 7: 263–284.
- Hirsch M, Carli P, Nizard R, Riou B, Baroudjian B, Baubet T et al. (2015). The medical response to multisite terrorist attacks in Paris. *Lancet Lond Engl.* 386: 2535–2538.
- Keneally R, Szpisjak D. (2013). Thoracic trauma in Iraq and Afghanistan. *J Trauma Acute Care Surg.* 74: 1292–1297.
- Lesquen HD, Beranger F, Berbis J, Boddaert G, Poichotte A, Pons F et al. (2016). Challenges in war-related thoracic injury faced by French military surgeons in Afghanistan (2009–2013). *Injury.* 47: 1939–1944.
- Lo Cicero J 3rd, Mattox KL. (1987). Epidemiology of chest trauma. *Surg Clin North Am.* 69: 15.
- Mykhailosov RM, Velikodny OM, Bilenky VA, Negoduyko VV, Borodai VO. (2015). Utility model patent No. 105452 (UA). A flexible device for removing ferromagnetic foreign bodies. Submitted on August 4, 2015; Publ. 25.03.2016. *Bul. No. 6.*
- Poon H, Morrison JJ, Apodaca AN, Khan MA, Garner JP. (2013). The UK military experience of thoracic injury in the wars in Iraq and Afghanistan. *Injury.* 44: 1165–1170.
- Stephanopoulos PK, Hadjigeorgiou GF, Philippakis K, Giftokostas D. (2014). Gunshot wounds: a review of ballistics associated with penetrating trauma. *Journal of Acute Disease.* 3: 178–185.

Відомості про авторів:

Лурін Ігор Анатолійович – д.мед.н., віце-президент НАМН України, проф. ДУ «Науково-практичний центр профілактичної та клінічної медицини» Державного управління справами, генерал-майор медичної служби. Адреса: м. Київ, вул. Верхня, 5. <https://orcid.org/0000-0001-6280-1725>.

Хорошун Едуард Миколайович – к.мед.н., доц. каф. хірургії №4 Харківського НМУ, полковник медичної служби, начальник Військово-медичного клінічного центру Північного регіону Командування медичної служби ЗСУ. Адреса: м. Харків, вул. Культури, 5. <https://orcid.org/0000-0003-1258-1319>.

Негодуйко Володимир Володимирович – д.мед.н., доц. каф. хірургії №4 Харківського НМУ, начальник клініки невідкладної медичної допомоги Військово-медичного клінічного центру Північного регіону Командування медичної служби ЗСУ. Адреса: м. Харків, пр. Московський, 195. <https://orcid.org/0000-0003-4540-5207>.

Макаров Віталій Володимирович – проф. зав. каф. хірургії №4 Харківського НМУ. Адреса: м. Харків, пр. Московський, 195. <https://orcid.org/0000-0002-4224-0294>.

Бунін Юрій Володимирович – начальник операційного відділення Військово-медичного клінічного центру Північного регіону Командування медичної служби ЗСУ, полковник медичної служби ЗСУ. Адреса: м. Харків, вул. Культури, 5. <https://orcid.org/0000-0002-1807-437X>.

Салютін Руслан Вікторович – д.мед.н., ст.н.с., заст. директора з організаційної та клініко-інноваційної роботи ДУ «Національний інститут хірургії та трансплантології імені О. О. Шалімова НАМН України». Адреса: м. Київ, вул. Героїв Севастополя, 30.

Тертишний Сергій Володимирович – к.мед.н., полковник медичної служби, лікар хірург-травматолог вищої категорії Військово-медичний клінічний центр Південного регіону Командування медичної служби ЗСУ. Адреса: м. Одеса, вул. Пироговська, 2/2. <https://orcid.org/0000-0002-4949-5409>.

Стаття надійшла до редакції 30.09.2022 р., прийнята до друку 19.12.2022 р.