

UDC 616.423–007:616.34]-053.2–089

O.S. Godik^{1,2}, D.S. Diehtiarova¹, A.H. Rusyn²

Digital subtraction angiography of intrahepatic portal vein as the key visualization for mesoportal shunting in children with extrahepatic portal vein obstruction

¹*Bogomolets National Medical University, Kyiv, Ukraine*

²*National Children's Specialized Hospital «ОКХМАТДІТ», Kyiv, Ukraine*

Paediatric Surgery(Ukraine).2024.1(82):27-32; doi 10.15574/PS.2024.82.27

For citation: Godik OS, Diehtiarova DS, Rusyn AH. (2024). Digital subtraction angiography of intrahepatic portal vein as the key visualization for mesoportal shunting in children with EHPVO. Paediatric Surgery (Ukraine). 1(82): 27–32; doi: 10.15574/PS.2024.82.27.

An early consideration in pediatric patients with extrahepatic portal vein obstruction (EHPVO) is to be given for mesoportal shunt. A careful investigation is required to prove intrahepatic portal system patency. Conventional noninvasive imaging is not adequately reliable in assessing patency of the intrahepatic portal venous system. Retrograde portography in children brings additional invasive procedure. Antegrade, direct intraoperative digital subtraction angiography for mesoportal shunt feasibility assessment is poorly presented in literature.

Aim – to improve the rate of success of mesoportal shunting in children with EHPVO by analyzing our own experience in intraoperative digital subtraction angiography of the intrahepatic branches of the portal vein for the final assessment of the mesoportal shunting feasibility.

Materials and methods. 7 pediatric patients with EHPVO were selected for the study. Angiographies and surgeries in selected patients were performed within single center in a period from May 2022 to July 2023. Mean follow up of successful mesoportal shunting was 12.38 ± 1.46 months.

Results. All patients were males. Men age at surgery was 8.71 ± 1.72 years. 5 (71.4%) patients manifested bleeding episodes as the first sign of portal hypertension. In all patients ultrasound revealed splenomegaly and suspected portal hypertension for reduced volumetric portal flow. All 7 patients had high grade. Liver function was normal in all patients, and in none thrombophilia was confirmed. CT scans suspected patent left intrahepatic branch (Rex-zone). Digital subtraction angiography approved mesoportal shunt feasibility in 4 (57.1%) patients. The follow up period was 13.5 ± 2.9 months.

Conclusions. Digital subtraction angiography of intrahepatic portal vein is effective visualization method to achieve with radiologic evidence of intrahepatic portal branches patency and make the decision on mesoportal shunting when favorable anatomy proved.

The research was carried out in accordance with the principles of the Helsinki Declaration. The study protocol was approved by the Local Ethics Committee of the participating institution. The informed consent of the patient was obtained for conducting the studies.

No conflict of interests was declared by the authors.

Keywords: extrahepatic portal vein obstruction, portal hypertension, mesoportal shunting, digital subtraction angiography, intrahepatic portal vein, children.

Цифрова субтракційна ангіографія внутрішньопечінкової портальної вени як ключовий метод візуалізації для мезопортального шунтування в дітей із допечінковою формою портальної гіпертензії

О.С. Годік^{1,2}, Д.С. Дєгтярьова², А.Г. Русин²

¹*Національний медичний університет імені О.О. Богомольця, м. Київ, Україна*

²*Національна дитяча спеціалізована лікарня «ОХМАТДИТ», м. Київ, Україна*

Пацієнтам дитячого віку з допечінковою формою портальної гіпертензії слід вже на ранніх стадіях розглядати можливість виконання мезопортального шунтування. Необхідне ретельне обстеження, щоб підтвердити прохідність внутрішньопечінкової портальної

Original articles. Abdominal surgery

системи. Звичайна неінвазивна візуалізація не є надійною для оцінювання прохідності внутрішньопечінкової системи порталльної вени. Ретроградна портографія в дітей передбачає додаткову інвазивну процедуру. Антеградна, пряма інтраопераційна цифрова субтракційна ангиографія для оцінювання можливості мезопортального шунта недостатньо висвітлена в літературі.

Мета – поліпшити успішність виконання мезопортального шунтування в дітей із порталльною гіпертензією шляхом аналізу власного досвіду використання інтраопераційної цифрової субтракційної ангиографії внутрішньопечінкових гілок порталльної вени для остаточного оцінювання можливості виконання мезопортального шунтування.

Матеріали та методи. До дослідження залучено 7 дітей, яким виконано порталльну ангиографію в період із травня 2022 р. по липень 2023 р., безпосередньо перед виконанням оперативного втручання на базі НДСЛ «ОХМАТДИТ». Період спостереження за пацієнтами становив $12,38 \pm 1,46$ місяця.

Результати. Усі пацієнти були чоловічої статі. Середній вік на момент операції становив $8,71 \pm 1,72$ року. У 5 (71,4%) пацієнтів першим проявом порталльної гіпертензії був епізод кровотечі. У всіх пацієнтів за результатами ультразвукового дослідження виявлено спленомегалію та підозру на порталльну гіпертензію у вигляді зниження об'ємного порталльного кровотоку. У всіх 7 хворих відзначено варикозне розширення вен високого ступеня. Функція печінки була нормальною у всіх пацієнтів, у жодного не підтверджено тромбофілії. За даними комп'ютерної томографії виявлено підозру на прохідну ліву внутрішньопечінкову гілку порталльної вени (Рекс-зона). За результатами цифрової субтракційної ангиографії мезопортальне шунтування виконано 4 (57,1%) хворим. Термін спостереження за успішними мезопортальними шунтами становив $13,5 \pm 2,9$ місяця.

Висновки. Цифрова субтракційна ангиографія внутрішньопечінкових гілок порталльної вени є ефективним візуалізаційним методом для отримання радіологічного підтвердження прохідності внутрішньопечінкової порталльної системи та прийняття рішення про виконання мезопортального шунтування в разі, коли доведено сприятливу анатомію.

Дослідження виконано відповідно до принципів Гельсінської декларації. Протокол дослідження ухвалено Локальним етичним комітетом зазначеної в роботі установи. На проведення досліджень отримано інформовану згоду батьків дітей.

Автори заявляють про відсутність конфлікту інтересів.

Ключові слова: допечінкова форма порталльної гіпертензії, мезопортальне шунтування, цифрова субтракційна ангиографія, внутрішньопечінкова порталльна вена, діти.

Introduction

Pediatric symptomatic portal hypertension mostly results from extrahepatic portal vein obstruction (EHPVO). Portal hypertension leads to numerous complications, the most life-threatening of which is the bleeding from esophageal varices [5,11,13]. Surgical treatment is the key to resolve all the pathologic symptoms of portal hypertension. Mesoportal shunt is a golden standard of surgical treatment, as it is the only shunt that restores the physiological liver blood flow [13,14,21]. A careful investigation is required to prove intrahepatic portal system patency, as it is the predisposing condition for successful mesoportal shunt [4,5,15]. Conventional noninvasive imaging is not very reliable in assessing patency of the intrahepatic portal venous system. Direct portography and its role in diagnosis of liver diseases was first described by K.F. Aronsen et al. in 1967 [1]. One of the first publications on digital subtraction angiography of the portal venous system was made by W.D. Foley et al. in 1983 [12]. All mentioned studies involved adult patients. No publications were found by the authors of current study dedicated to digital subtraction angiography of the portal venous system as assessment of mesoportal shunting feasibility.

The **aim** of the study – to improve the rate of success of mesoportal shunting in children with EHPVO by analyzing our own experience in intraoperative digital subtraction angiography of the intrahepatic branches of the portal vein for the final assessment of the possibility of mesoportal shunting feasibility.

Materials and methods of the study

Patients' data was collected from case-records retrospectively. Out of 25 children, who underwent surgical treatment for symptomatic portal hypertension in our center in mentioned period, 7 (28%) were selected for the study as they were initially assessed for mesoportal shunt. All portal angiographies and surgeries were performed in a period from May 2022 to July 2023. The follow up period of successful mesoportal shunts was $13,5 \pm 2,9$ months.

For all patients, the following criteria were analyzed: gender, age at surgical procedure, clinical presentation, endoscopic visualization results, result of treatment.

Examination was as follows. Laboratory tests according to standard clinic's protocol. US was performed using Samsung RS80A-UA, convex transducer (mean frequencies 1–7 MHz) to all patients in gray scale, color Doppler, and spectral Doppler tracings, both at initial screening and at later stages of treatment and follow-up. To assess the grade of esophageal varices and gastric mucosa endoscopy was performed to all patients, with primary variceal bleeding prophylaxis (variceal band ligation). Contrast-enhanced computed tomography (CT) was performed to all patients before surgery with Siemens somatom definition AS. Intraoperation digital subtraction portal angiography was performed with Digital X-ray surgical device like C-arc SYMBOL FP L SURGICAL.

Surgical procedure was performed according to the technique for mesoportal shunt described by authors

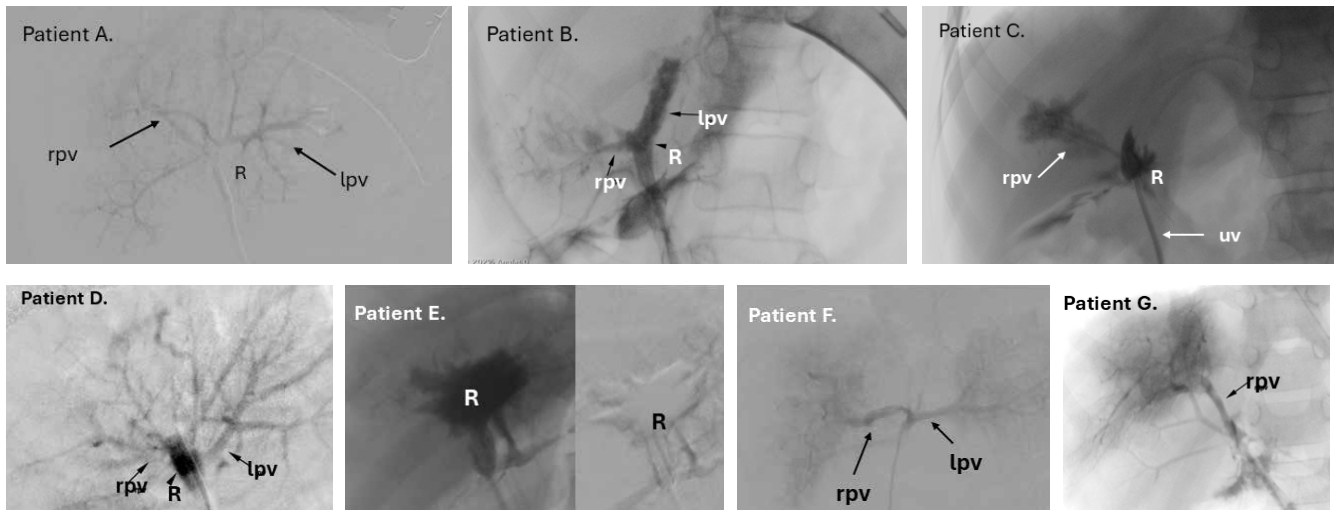


Fig. 1. Digital subtraction angiography of intrahepatic portal vein in the study group patients. Digital subtraction image on posteroanterior (PA) projection through catheterization of the round ligament (recanalized umbilical vein) shows where mentioned: the Rex recess (R), left portal vein (lpv) and right portal vein (rpv). *Patient A.*: Rex recess (R) and the communication between the left (lpv) and right (rpv) portal veins; *Patient B.*: Rex recess (R) and the right (rpv) portal vein. No segmental branches in left (lpv) portal vein; *Patient C.*: Rex recess (R) and weak right (rpv) portal vein with poor segmental branches; *Patient D.*: Rex recess (R) and the communication between the left (lpv) and right (rpv) portal veins; *Patient E.*: Rex recess (R) without patent branches. *Patient F.*: Rex recess (R) and the communication between the left (lpv) and right (rpv) portal veins; *Patient G.*: Rex recess (R) and right (rpv) portal vein with patent branches

[8]: laparotomy, round ligament is dissected to the Rex-recessus, its lumen is opened to reach the revision. If left portal vein branch and its outflow were considered patent and satisfactory, intraoperation digital subtraction angiography of intrahepatic portal vein is performed to visualize its branches. Polychlorvinyl catheter 4–6 Fr is inserted to the lumen of round ligament and fixed by a temporary ligature. Intrahepatic portal branches are flushed slowly by 5 ml of heparine, in solution counted 5 IU per 1 kilogram of patient’s weight. After 5–10 ml of contrast substance «Tomohexol» soluted 1:1 to sterile saline is administered. The visualization result is being assessed immediately by the operating surgeon.

The Committee on Clinical Investigation of Bogomolets National Medical University approved this study (Protocol No.141 27.01.2021). All the studies were conducted according to implemented guidelines in consideration of GCP-ICH and Declaration of Helsinki and

declaration of Istanbul. The written informed consent of all participants’ parents/guardians was achieved.

Results of the study

Patients’ characteristics are summarized in Table 1. All 7 (100%) of patients were males. Mean age at surgery was 8.71 ± 1.72 years. None had umbilical catheter in anamnesis, therefore EHPVO was considered as idiopathic. 5 (71.4%) patients manifested bleeding episodes as the first sign of portal hypertension, 3 of them were admitted with signs of acute bleeding. Others (n=2, 28.6%) were directed to examination for accidentally detected splenomegaly either anemia. One of the latter ones underwent bone marrow puncture to reveal the nature of cytopenia. In all patients US revealed splenomegaly and suspected portal hypertension for reduced volumetric portal flow, fibrotic changes of periportal liver parenchyma, or collaterals with cavernoma formation. All 7 patients had

Table 1

Characteristics of the study group patients

Patient	Age at surgery, years	Clinical presentation	Primary variceal bleeding prophylaxis, Procedures, quantity
<i>Patient A.</i>	10	Variceal bleeding, splenomegaly, hypersplenism	Band ligation, 4
<i>Patient B.</i>	11	Variceal bleeding, splenomegaly	Band ligation, 3
<i>Patient C.</i>	11	Variceal bleeding, splenomegaly, hypersplenism	Band ligation, 1
<i>Patient D.</i>	5	Splenomegaly, esophageal varices	Band ligation, 2
<i>Patient E.</i>	16	Splenomegaly, hypersplenism, esophageal varices	Band ligation, 2
<i>Patient F.</i>	5	Variceal bleeding, splenomegaly	Band ligation, 1
<i>Patient G.</i>	3	Variceal bleeding, splenomegaly	Band ligation, 1

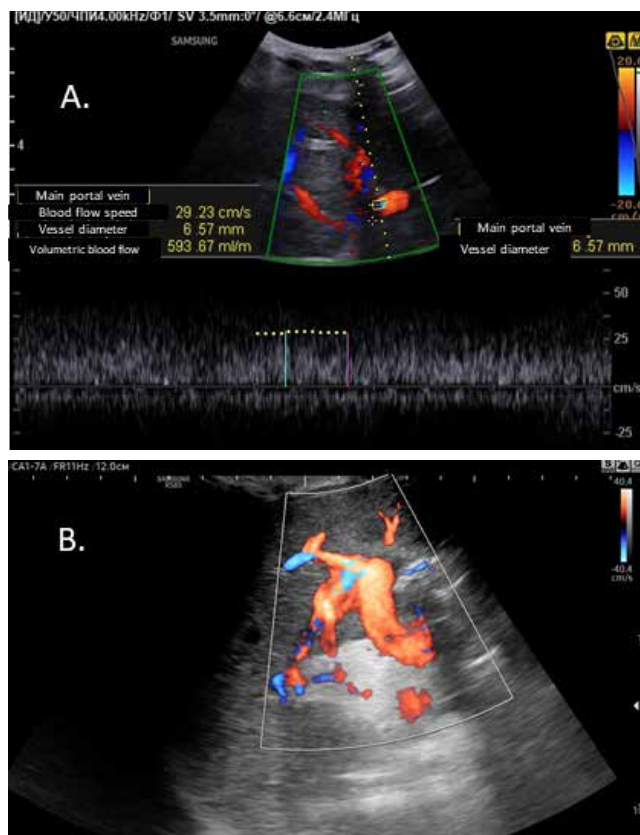


Fig. 2. Doppler Ultrasound of Mesoportal shunts. Doppler US, Samsung RS80A-UA, convex transducer (mean frequencies 1–7 MHz). A: *Patient A.*, 1 month after mesoportal shunting. Volumetric blood flow in newly formed portal vein (internal jugular vein graft) is assessed satisfactory, up to 593 vk/minute; B: *Patient G.*, 12 months after mesoportal shunting. Mesoportal shunt is visualized all length throughout well, without filling defects or narrowings, the direction of the flow is hepatopetal

Table 2

Shunting procedures considered in patients of the study group patients

Patient	Surgery performed	Follow-up, months
<i>Patient A.</i>	Mesoportal shunt	6
<i>Patient B.</i>	Splenorenal shunt	12
<i>Patient C.</i>	Splenorenal shunt	17
<i>Patient D.</i>	Mesoportal shunt	13
<i>Patient E.</i>	Splenorenal shunt	14
<i>Patient F.</i>	Mesoportal shunt	15
<i>Patient G.</i>	Mesoportal shunt	20

grade II – grade III varices according to endoscopic data, endoscopic band ligation was applied to all, procedures performed varied from 1 to 4. In 5 cases surgery was urgent. By the time of surgery cytopenia manifested in 4 (57.1%) patients with mean thrombocytes count of 65.6 ± 7.8 and leucopenia with leucocytes count less than $1.5 \times 10^9/l$. All patient presented anemia, with mean he-

moglobin level of 78.1 ± 2.9 g/l. Liver function was normal in all patients, and in none thrombophilia was confirmed.

In 3 (42.8%) patients with acute variceal bleeding short-term conservative treatment by means of octreotide 2 mg/kg/hour in continuous intravenous infusion and RBC (red blood cell) transfusion at the rate of 5 ml/kg.

CT scans suspected patent left intrahepatic branch (Rex-zone), therefore all were assessed for mesoportal shunting. Visualization results of digital subtraction angiography of intrahepatic portal vein are represented on Figure 1.

According to results of digital subtraction angiography of intrahepatic portal vein mesoportal shunt was performed in 4 (57.1%) patients, overall results are presented in Table 2.

All shunts were followed-up by US regularly according to Institutional follow-up protocol (Figure 2).

The follow up period of successful mesoportal shunts was 13.5 ± 2.9 months. By the end of the study cytopenia resolved, spleen size normalized in all patients. In those, who reached 1 year after surgery endoscopy showed involution of esophageal varices.

Discussion

In children, portal hypertension is defined as a pathological increase of the pressure in the portal system, with a pressure gradient between the portal vein and inferior vena cava greater than 5 mmHg [11,14]. Pediatric EHPVO is idiopathic in most of the cases, the risk factors for EHPVO development are neonatal umbilical vein catheterization, transfusions, bacterial infections, dehydration, and thrombophilia [14,16,21]. In all patients (n=7) of our study none of mentioned factors were detected or proved, therefore EHPVO was considered as idiopathic. The main clinical manifestations of EHPVO are upper gastrointestinal bleeding and splenomegaly [5,11,13,14,21]. In our group, 5 (71.4%) patients manifested bleeding as the first sign of EHPVO; all seven had splenomegaly, with clinically significant hypersplenism.

Only surgical treatment can resolve all the threatening symptoms of portal hypertension [7,13,16]. For patients with EHPVO, early consideration should be given to surgical treatment with a meso-Rex bypass [3,5,9,15,19,21], which is called an «ideal shunt», which returns the portal blood flow into the liver, and resolves all the consequences of portal hypertension, such as varices, hypersplenism, cytopenia, growth failure and encephalopathy [8,13,16,18,21]. In addition, it is used in post living donor liver transplant patients with portal complications [6,8]. At the same time, the feasibility of mesoportal shunt depends on favorable vascular anatomy and residual patency [4,5,10,13,15].

A careful investigation is required to prove Rex-zone patency. The goals of preoperative mesoportal shunt imaging are to determine the extent of thrombosis to the splanchnic venous system and intrahepatic portal branches. Patency of the splenic and mesenteric veins must be assessed, as well as that of the recessus of Rex and the intrahepatic portal branches [5,6,9]. Doppler ultrasound (US) can demonstrate heterogeneity of the liver in chronic liver disease, and Doppler examination is useful to assess portal vein patency and direction of flow [8,19,22]. This is usually diagnostic of EHPVO, but occasionally large collaterals can be misinterpreted as a patent portal vein. In cavernous transformation of the portal vein, the Doppler waveform typically displays a characteristic flat waveform of hepatopetal flow, with reduction in normal portal flow velocity [22]. Other US findings that are predictive of the development of varices include omental thickening, gall bladder wall thickening and spontaneous splenorenal shunts [20]. US is not enough to assess left portal vein patency, as in only 63% of patients Rex patency can be suggested but not proved using this method of visualization [5,8,13].

In the last decade, CT has significantly improved the visualization capabilities of the Rex zone, however, the authors noted that the imaging results CT or magnetic resonance imaging (MRI) in patients with a large cavernoma of the portal vein are sometimes not reliable because it challenging to visualize the hypodynamic circulation in intrahepatic branches of the portal vein and Rex zone [4,23]. In some patients from the study of R. Superina et al. [20], according to the results of preoperative CT scans, the Rex zone was not recognized as passable or was not determined. Other researchers believe intraoperative direct visualization is the best by the method of determining the suitability of the left branch of the portal vein to the mesoportal shunt [20,23]. A. Bertocchini et al. [2] showed that the Rex recessus is observed on CT only when both the vein is large enough in caliber and in the absence of perivenous vascular changes. In our study CT was performed in all children that led to initial assumption their intrahepatic portal system might be patent.

According to the study of I.J. Chaves et al. [5], both MRI and CT were described as effective modalities in the evaluation of children with EHPVO, as both imaging modalities can provide multiplanar and volume-rendered reformatted images yielding an anatomical road map of the splanchnic and portal venous anatomy, and they can be utilized to create 3-D reconstructions. Other authors [3,17] concluded, that MRI has shown to be unsuitable for the assessment of the intrahepatic portal vein in pediatric patients.

Noninvasive imaging, such as US, CT, MRI, does not guarantee the precise assessment of the intrahepatic portal venous system patency and/or the Rex segment of the left portal vein, which is caused by the hypodynamic circulation in patients with cavernoma. Retrograde portography is considered as being the gold standard imaging technique in these cases. Retrograde filling of the intrahepatic portal veins is achieved via a catheter wedged in the relevant hepatic veins [2–4,17]. But in children it becomes an additional invasive procedure with all its potentials risks, which requires additional general anesthesia [3]. In addition, interventional radiologists are required to perform this diagnostic procedure [6].

No publications were found by the authors of current study dedicated to digital subtraction angiography of the portal venous system as assessment of mesoportal shunting feasibility. in children which would require general anesthesia.

Postoperative imaging may be achieved with Doppler US to show the patency of the shunt. The flow in the left portal vein is reversed and moves toward the right portal vein. Within a few days after surgery it can be clearly detected the flow is increased, the intrahepatic portal vein branches are expanding progressively, and the size and conspicuity of the cavernous collaterals decrease [3,13,22]. The US follow-up was performed in all patients of our study with successful mesoportal shunts according to Institutional follow-up protocol.

Radiologists and pediatric surgeons should be familiar with this entity, understand the portal anatomy, surgical procedure, and recognize the pre- and postoperative imaging features [2,3].

Conclusions

Digital subtraction angiography of intrahepatic portal vein is effective visualization method to achieve with radiologic evidence of intrahepatic portal branches patency and make the decision on mesoportal shunting when favorable anatomy proved. Authors consider this method safe, fast and informative; made within a surgical procedure in children who were already assessed for a surgery with assumption of possible Rex-zone patency. In all children of the study group whose intrahepatic portal system was proved patent by digital subtraction angiography the mesoportal shunt was successful.

Funding. The present study was supported by the Ministry of Health of Ukraine (project no. 0122U001363 «Experimental justification of portal hypertension surgical treatment method in children according to molecular, morphological, and functional changes in liver»).

No conflict of interests was declared by the authors.

References/Література

1. Aronsen KF, Nylander G. (1967). Use of direct protography in diagnosis of liver diseases. *Radiology*. 88(1): 40–47. <https://doi.org/10.1148/88.1.40>.
2. Bertocchini A, Falappa P, Grimaldi C, Bolla G, Monti L, de Ville de Goyet J. (2014). Intrahepatic portal venous systems in children with noncirrhotic prehepatic portal hypertension: anatomy and clinical relevance. *Journal of pediatric surgery*. 49(8): 1268–1275. <https://doi.org/10.1016/j.jpedsurg.2013.10.029>.
3. Cárdenas AM, Epelman M, Darge K, Rand EB, Anupindi SA. (2012). Pre- and Postoperative Imaging of the Rex Shunt in Children: What Radiologists Should Know. *American Journal of Roentgenology*. 198(5): 1032–1037. doi: 10.2214/ajr.11.7963.
4. Carollo V, Marrone G, Cortis K, Mamone G, Caruso S, Milazzo M et al. (2019). Multimodality imaging of the Meso-Rex bypass. *Abdominal radiology (New York)*. 44(4): 1379–1394. <https://doi.org/10.1007/s00261-018-1836-1>.
5. Chaves IJ, Rigsby CK, Schoeneman SE, Kim ST, Superina RA, Ben-Ami T. (2011). Pre- and postoperative imaging and interventions for the meso-Rex bypass in children and young adults. *Pediatric Radiology*. 42(2): 220–232. doi: 10.1007/s00247-011-2283-0.
6. Dalzell C, Vargas PA, Soltys K, Di Paola F, Mazariegos G, Goldaracena N. (2022). Technical Aspects and Considerations of Meso-Rex Bypass Following Liver Transplantation With Left Lateral Segment Grafts: Case Report and Review of the Literature. *Frontiers in pediatrics*. 10: 868582. <https://doi.org/10.3389/fped.2022.868582>.
7. De Franchis R. (2010). Revising consensus in portal hypertension: report of the Baveno V Consensus Workshop on methodology of diagnosis and therapy in portal hypertension. *J Hepatol*. 53: 762–768. <https://doi.org/10.1016/j.jhep.2010.06.004>.
8. De Ville de Goyet J, Alberti D, Clapuyt P, Falchetti D, Rigamonti V, Bax NM et al. (1998). Direct bypassing of extrahepatic portal venous obstruction in children: A new technique for combined hepatic portal revascularization and treatment of extrahepatic portal hypertension. *Journal of Pediatric Surgery*. 33 (4): 597–601. doi: 10.1016/s0022-3468(98)90324-4.
9. De Ville de Goyet J, Martinet JP, Lacrosse M et al. (1998). Mesenterico-left intrahepatic portal vein shunt: original technique to treat symptomatic extrahepatic portal hypertension. *Acta Gastroenterol Belg*. 61: 13–16. URL: <https://pubmed.ncbi.nlm.nih.gov/9629766/>. PMID: 9629766.
10. Di Francesco F, Grimaldi C, de Ville de Goyet J. (2014). Meso-Rex Bypass – A Procedure to Cure Prehepatic Portal Hypertension: The Insight and the Inside. *Journal of the American College of Surgeons*. 218 (2): e23–e36. doi: 10.1016/j.jamcollsurg.2013.10.024.
11. Ferri PM, Ferreira AR, Fagundes EDT, Liu SM, Roquete MLV, Penna FJ. (2012). Portal vein thrombosis in children and adolescents: 20 years experience of a pediatric hepatology reference center. *Arquivos de Gastroenterologia*. 49(1): 69–76. doi: 10.1590/s0004-28032012000100012.
12. Foley WD, Stewart ET, Milbrath JR, SanDretto M, Milde M. (1983). Digital subtraction angiography of the portal venous system. *AJR: American journal of roentgenology*. 140(3): 497–499. <https://doi.org/10.2214/ajr.140.3.497>.
13. Godik OS, Diehtiarova DS, Dubrovin OG, Levytskii AF, Benzar IM. (2022). Peculiarities of mesoportal shunt surgical technique and its efficiency in treatment of children with portal hypertension. *Paediatric Surgery (Ukraine)*. 4 (77): 23–33. doi: 10.15574/PS.2022.77.23.
14. Grama A, Pirvan A, Sirbe C, Burac L, Ștefănescu H, Fufezan O et al. (2021). Extrahepatic Portal Vein Thrombosis, an Important Cause of Portal Hypertension in Children. *Journal of Clinical Medicine*. 10(12): 2703. doi: 10.3390/jcm10122703.
15. Guerin F, Bidault V, Gonzales E, Franchi-Abella S, De Lambert G, Branchereau S. (2013). Meso-Rex bypass for extrahepatic portal vein obstruction in children. *British Journal of Surgery*. 100 (12): 1606–1613. doi: 10.1002/bjs.9287.
16. Jhang J, Li L. (2022). Rex Shunt for Extra-Hepatic Portal Venous Obstruction in Children. *Children (Basel)*. 9 (2): 297. doi: 10.3390/children9020297.
17. Kathemann S, Lainka E, Ludwig JM, Wetter A, Paul A, Hoyer PF et al. (2019, Aug). Imaging of the Intrahepatic Portal Vein in Children with Extrahepatic Portal Vein Thrombosis – Comparison of Magnetic Resonance Imaging and Retrograde Portography. *Journal of Pediatric Surgery*. 54(8): 1686–1690. Epub 2018 Oct 30. doi: 10.1016/j.jpedsurg.2018.10.049. PMID: 30497819.
18. Lautz TB, Sundaram SS, Whittington PF, Keys L, Superina RA. (2009). Growth impairment in children with extrahepatic portal vein obstruction is improved by mesenterico-left portal vein bypass. *Journal of Pediatric Surgery*. 44 (11): 2067–2070. <https://doi.org/10.1016/j.jpedsurg.2009.05.016>.
19. McKiernan P, Abdel-Hady M. (2015). Advances in the management of childhood portal hypertension. *Expert review of gastroenterology & hepatology*. 9(5): 575–583. <https://doi.org/10.1586/17474124.2015.993610>.
20. Superina R, Bambini DA, Lokar J, Rigsby C, Whittington PF. (2006). Correction of extrahepatic portal vein thrombosis by the mesenteric to left portal vein bypass. *Annals of surgery*. 243(4): 515–521. <https://doi.org/10.1097/01.sla.0000205827.73706.97>.
21. Superina RA, Alonso EM. (2006). Medical and surgical management of portal hypertension in children. *Current Treatment Options in Gastroenterology*. 9(5): 432–443. doi: 10.1007/bf02738533.
22. Tilak GS, Bellah RD. (2013). Sonography of Pediatric Portal Hypertension. *Ultrasound Clinics*. 8(3): 285–297. doi: 10.1016/j.cult.2013.03.003.
23. Wu H, Zhou N, Lu L, Chen X, Liu T, Zhang B et al. (2021). Value of preoperative computed tomography for meso-Rex bypass in children with extrahepatic portal vein obstruction. *Insights into imaging*. 12(1): 109. <https://doi.org/10.1186/s13244-021-01057-8>.

Відомості про авторів:

Годік Олег Святославович – к.мед.н., доц. каф. дитячої хірургії НМУ ім. О.О. Богомольця; лікар-трансплантолог, лікар-хірург дитячий відділення ургентної хірургії НДСЛ «ОХМАТДИТ». Адреса: м. Київ, вул. В. Чорновола, 28/1. <https://orcid.org/0000-0002-1084-9484>.

Дегтярєва Дар'я Сергіївна – PhD, лікар-хірург дитячий відділення ургентної хірургії НДСЛ «ОХМАТДИТ». Адреса: м. Київ, вул. В. Чорновола, 28/1. <https://orcid.org/0000-0002-2356-0874>.

Русин Анастасія Георгіївна – лікар-рентгенолог, зав. відділення променевої діагностики Центру радіології НДСЛ «ОХМАТДИТ». Адреса: м. Київ, вул. В. Чорновола, 28/1. <https://orcid.org/0000-0002-3407-3895>.

Стаття надійшла до редакції 27.12.2023 р., прийнята до друку 12.03.2024 р.