

UDC 617.586-007.54+616.71-089.85

A.P. Liabakh<sup>1</sup>, O.A. Turchyn<sup>1</sup>, T.M. Omelchenko<sup>2</sup>

# Calcaneal lengthening osteotomy in the treatment of flexible flatfoot in children

<sup>1</sup>SI «The Institute of Traumatology and Orthopedics of NAMS of Ukraine», Kyiv<sup>2</sup>Bogomolets National Medical University, Kyiv, Ukraine.

Paediatric Surgery (Ukraine). 2025. 4(89): 41-46. doi: 10.15574/PS.2025.4(89).4146

**For citation:** Liabakh AP, Turchyn OA, Omelchenko TM. (2025). Calcaneal lengthening osteotomy in the treatment of flexible flatfoot in children. Paediatric Surgery (Ukraine). 4(89): 41-46. doi: 10.15574/PS.2025.4(89).4146.

**Aim** – to analyze the skiological, functional, and clinical results of calcaneal lengthening osteotomy in children with flexible flatfoot (FF).

**Material and methods.** The retrospective study includes 10 patients (17 cases) with FF who underwent calcaneal lengthening osteotomy by the Evans-Mosca technique. All patients had the shortening of the m. triceps surae. The age of patients ranged from 8 to 16 years (mean 12±0.7 years); there were 9 boys and 1 girl. Evaluation of the results was carried out on the dynamics of vertical and horizontal talo-1st-metatarsal angles (TMA), os calcis inclination angle (CIA), AOFAS scale (hindfoot and ankle), Foot Function Index (17-I FFI, Italian version), VAS (pain) in terms of 2 to 4 years.

**Results.** The operation caused a pronounced cosmetic, radiological, and functional effect. All patients and their parents were satisfied with the result of the surgery. There is an improvement in radiological parameters on average: vertical TMA from 21,9 to 1,9°; horizontal TMA from 21,1 to 3°; CIA from 6,8 to 15,3°. The dynamics of the foot function by average: increasing by AOFAS scale from 69,3 to 95,1; improvements for FFI from 14,9 to 2%; reduction of pain by VAS from 3,8 to 0,8. Effective foot extension increased from 0,5 to 8,9°. The difference between the averages was significant (p<0,001).

**Conclusion.** Os calcis lengthening osteotomy is an effective operation in the treatment of symptomatic FF in children, which provides a significant reduction in pain, good clinical and radiological results. The advantages of os calcis lengthening osteotomy are simple surgical techniques and a low risk of neurovascular complications.

The study was conducted in accordance with the Declaration of Helsinki. The protocol was approved by the Local Ethics Committee. Written informed consent was obtained from the children's legal guardians.

The authors declare no conflict of interest.

**Keywords:** children, flatfoot, os calcis, osteotomy.

## Подовжувальна остеотомія п'яtkової кістки в лікуванні гнучкої плоскої стопи в дітей

A.П. Лябах<sup>1</sup>, О.А. Турчин<sup>1</sup>, Т.М. Омельченко<sup>2</sup><sup>1</sup>ДУ «Інститут травматології та ортопедії НАМН України», м. Київ<sup>2</sup>Національний медичний університет імені О.О. Богомольця, м. Київ, Україна

**Мета** – проаналізувати скіологічні, функціональні та рентгенологічні результати подовжувальної остеотомії п'яtkової кістки і дітей із гнучкою плоскою стопою (ПС).

**Матеріал і методи.** Ретроспективне дослідження охоплює 10 пацієнтів (17 стоп) із гнучкою ПС, яким виконали подовжувальну остеотомію п'яtkової кістки за Evans-Mosca. Всі пацієнти мали укорочення m. triceps surae. Вік пацієнтів становив 8–16 років (у середньому 12±0,7 років); 9 хлопчиків і 1 дівчинка. Оцінку результатів проводили за динамікою вертикального та горизонтального таранно-метатарзального кутів (ТМК), кута інклінації п'яtkової кістки (ІПК), шкалами AOFAS (задній відділ стопи та гомілковостопний суглоб), Foot Function Index (17-I FFI, Italian version), візуальною аналоговою шкалою в терміни від 2 до 4 років.

**Результати.** Операція мала вагомий косметичний, рентгенологічний та функціональний ефект. Усі пацієнти та їхні батьки були задоволені результатом операції. Простежено покращення рентгенологічних показників у середньому: вертикального ТМК від 21,9 до 1,9°; горизонтального ТМК від 21,1 до 3°; кута ІПК від 6,8 до 15,3°. Динаміка функції стопи в середньому: покращення за шкалою

*Original articles. Orthopedics*

АOFAS від 69,3 до 95,1; покращення за FFI від 14,9 до 2%; зменшення болю за ВАШ від 3,8 до 0,8 балу. Ефективне розгинання стопи збільшилось від 0,5 до 8,9°. Різниця між середніми була суттєвою ( $p < 0,001$ ).

**Висновок.** Подовжувальна остеотомія п'яtkової кістки є ефективною операцією в лікуванні симптоматичної ПС у дітей, яка значно зменшує біль, сприяє гарним клінічним та рентгенологічним результатам. Перевагами подовжувальної остеотомії п'яtkової кістки є проста хірургічна техніка та низький ризик нейросудинних ускладнень.

Дослідження виконано відповідно до принципів Гельсінської декларації. Протокол схвалено місцевим етичним комітетом. Отримано письмову інформовану згоду від законних представників дітей.

Автори заявляють про відсутність конфлікту інтересів.

**Ключові слова:** діти, плоска стопа, п'яtkова кістка, остеотомія.

## Introduction

Flexible flatfoot (FF) is a common pathology among children and adolescents, occurring in approximately 12.5% of all visits to orthopedists [6]. The approach to the treatment of FF in children is predominantly conservative: orthotics, adequate footwear, physiotherapy, etc. There is no evidence of the effectiveness of conservative treatment of FF in the literature, rather it produces a palliative effect. Quite a lot of people have FF, which does not limit their daily activity and does not interfere with sports [14]. The question of the need for treatment of asymptomatic FF in children remains controversial, as it is impossible to predict the age-related evolution of flatfoot. However, surgeons dealing with foot and ankle pathology are well aware that over time, even minimal deformity can cause pain symptoms.

The indication for surgical treatment is pain, dysfunction, or severe deformity that prevents the use of shoes. In 1959, D. Evans developed and began to use the os calcis osteotomy with its lengthening for the treatment of FF, but the results of this operation were published in 1975 [5]. He believed that one of the manifestations of FF is the shortening of the lateral column and, accordingly, the alignment of its length should provide correction of the abduction of the forefoot and normalize the displacement in the talonavicular joint. This assumption has been confirmed and developed hereinafter in biomechanical and clinical studies [13,14].

In children with FF, complaints of pain and dysfunction are associated with shortening of m. triceps surae. Harris R.I. and Beath T. classify this type of deformation as flexible flatfoot with short tendo Achillis [7]. According to their data, this type of flatfoot is present in 25% of people with FF. In such cases, skeletal reconstruction is combined with lengthening of the tendo Achilles [3,4,8]. Ensuring sufficient extension of the foot is required to achieve plantigrade foot. There is one study in which the range of motion in the ankle joint after calcaneal lengthening osteotomy [8].

**The aim** is to analyze the skialogical, functional, and clinical results of calcaneal lengthening osteotomy in children with FF.

## Material and methods of the study

The retrospective study includes 10 patients (17 cases) with FF who underwent inpatient treatment at the clinic of the SI «The Institute of Traumatology and Orthopedics of NAMS of Ukraine» (SI «ITO NAMS of Ukraine») in the period 2004–2023. The age of patients ranged from 8 to 16 years (mean  $12 \pm 0.7$  years); there were 9 boys and 1 girl.

*Inclusion criteria:* medial arch lowering, flexible hindfoot, forefoot abduction; the corresponding values of the vertical and horizontal talo-1<sup>st</sup>-metatarsal angles (TMA), os calcis inclination angle (CIA), reducing the effective foot extension through shortening the m. triceps surae. Differentiation of the shortening m. triceps surae and m. gastrocnemius was carried out using a test with a flexed and extended knee joint.

X-ray dynamics was assessed by loading radiographs in antero-posterior, lateral and axial projections before surgery, 4, 8 weeks after surgery, and during follow-up examination. Vertical and horizontal TMA were defined as the intersection of the long axes of the 1<sup>st</sup> metatarsal and the talus on the lateral and antero-posterior radiographs of the foot. CIA was measured on the lateral radiograph between the line tangent to the lower surface of the os calcis and the plane of support. Measurements were performed in a vector graphic program after transferring digital radiographs. The measured values were exported to Microsoft Excel for further processing.

Foot function before and after surgery was assessed on the American Orthopedic Foot and Ankle Society scale (AOFAS) [9], Foot Function Index (17-I FFI, Italian version) [12], and Visual Analog Scale (VAS, pain) in terms of 2 to 4 years.

The applied assessment scales were numerical. AOFAS scale (domain hindfoot and ankle joint) includes assessment of pain, motor activity, range of motion, adaptation to the surface, stability) – the highest score is 100 points, perfect health. 17-I FFI, Italian version, the disability index was calculated as the arithmetic mean of three domains that characterize different aspects of pain; the highest score of 170 reflects the worst condition, the obtained value was converted into a percentage. VAS was

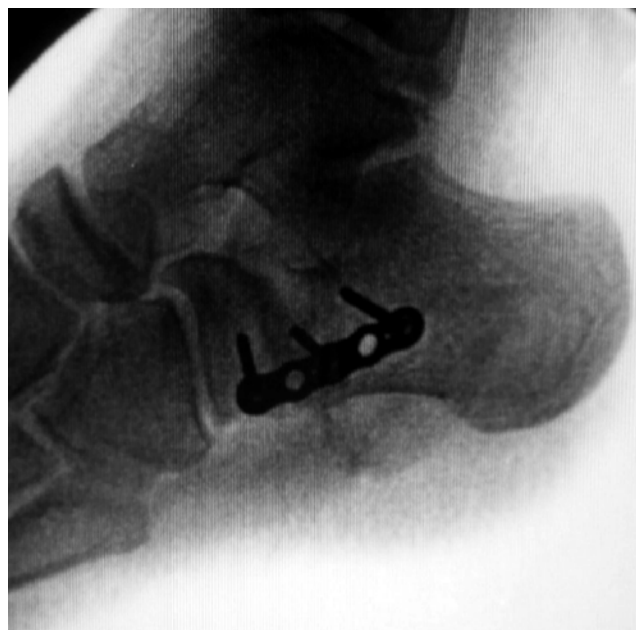used in the numerical version to assess the severity of pain, from the least 0 cm to the worst 10 cm.

Statistical analysis was performed using paired Student's *t*-test, which was considered significant when *p*-value was measured <0.05. For normally distributed continuous variables, the results are presented as the mean ± standard error of the mean ( $M \pm \sigma$ ) and 95% confidence interval (95% CI).

The study was conducted in accordance with the Declaration of Helsinki and approved by the Academic Council of the SI «ITO NAMS of Ukraine», the parents of all patients gave informed consent to be included in the study.

**Operation technique.** The operation is performed in the supine position with a pillow under the operated limb. A pneumatic tourniquet was used on the thigh. The modified Ollier approach was placed over the sinus tarsi approximately 1 cm proximal to the anterior process of the os calcis, protecting the n. suralis from injury. M. extensor digitorum brevis and sinus tarsi adipose tissue were separated from the anterior process of the os calcis. The tendons of the peroneal muscles retracted plantarly. The calcaneocuboid joint was identified but not opened.

A narrow elevator was used to find the gap between the middle and anterior facets of the os calcis, dissect the periosteum along a line that starts 1.5 cm proximal to the line of the calcaneocuboid joint and continues into the specified gap. The osteotomy plane was oriented along this line, which should run in the direction from the proximal-lateral to distal-medial edge of the os calcis. After completion of the osteotomy, Steinman pins were inserted into the os calcis fragments at a right angle, on which a distractor was mounted, with which the required level of correction was set. This level of correction was controlled radio-



**Fig. 1.** Intraoperative radiograph. Alignment of relative lengths of the talus and calcaneus

logically: the edge of the os calcis anterior process should be at the same level as the edge of the head of the talus (Fig. 1). The os calcis defect at the osteotomy site was filled with an auto- or allograft of a trapezoidal shape.

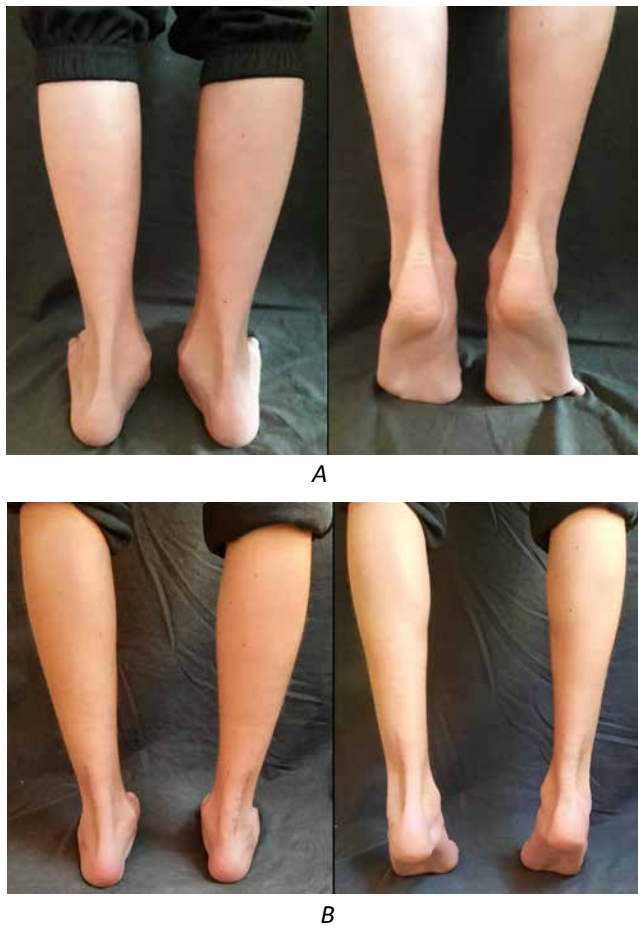
It is this arrangement of the osteotomy plane that allows, during correction, to establish the center of rotation at the same level as the center of the talus head, and not at the level of the medial calcaneal cortex. To prevent overcorrection, the graft should have a trapezoidal shape and a 2:1 base-to-top ratio. During the correction and insertion of the graft, the position of the calcaneocuboid joint was monitored to prevent dorsal subluxation of the

**Table**

Preoperative and final radiographic and clinical results

Index	$M \pm \sigma$ (min – max)	$p$ ( $\alpha=0.05$ )*
Vertical TMA (preop., degrees)	21.9±1.5 (9–37)	<0.001
Vertical TMA (final, degrees)	1.9±1.2 (0–19)	
Horizontal TMA (preop., degrees)	21.1±2.6 (10–46)	<0.001
Horizontal TMA (final, degrees)	3.0±1.1 (0–15)	
CIA (preop., degrees)	6.8±0.7 (2–12)	<0.001
CIA (final, degrees)	15.3±1.8 (0–29)	
AOFAS (preop., points)	69.3±1.7 (45–76)	<0.001
AOFAS (final, points)	95.1±0.8 (89–100)	
FFI (preop., %)	14.9±0.7 (11.9–21.3)	<0.001
FFI (final, %)	2±0.7 (0–11.2)	
VAS (preop., cm)	3.8±0.3 (2.5–6.0)	<0.001
VAS (final, cm)	0.8±0.2 (0–4)	
Ankle extension (preop., degrees)	0.5±0.9 ((-7)–5)	<0.001
Ankle extension (final, degrees)	8.9±0.7 (5–14)	

Note: \* – paired *t*-test.

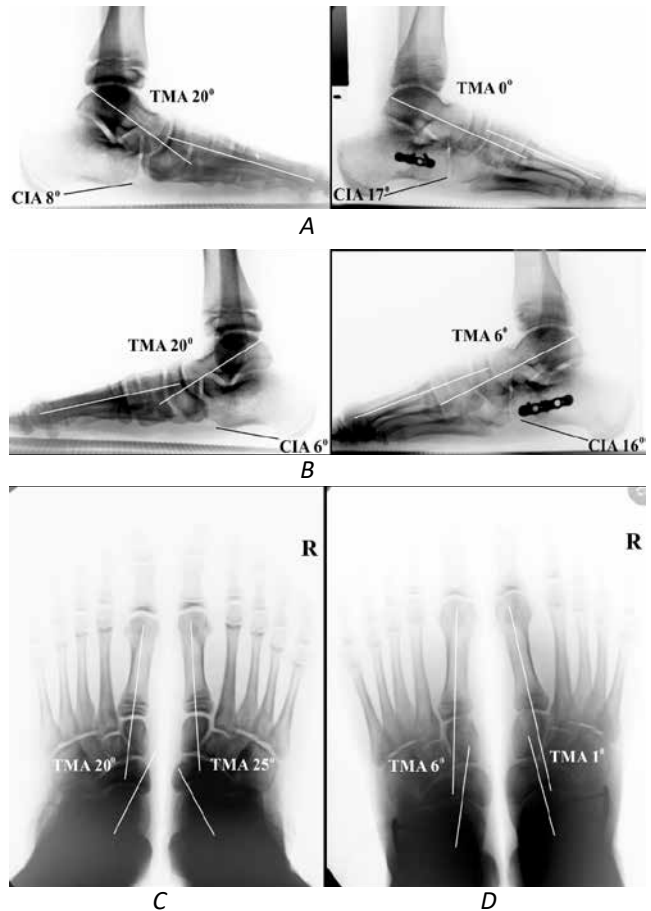


**Fig. 2.** Patient aged 10 years. Simultaneous correction of both feet. Allograft and LCP osteosynthesis are applied. The appearance and function of the feet before (A) and 1 year after (B) the lengthening of the os calcis osteotomy

distal calcaneal fragment. In the case of subluxation, the graft was removed, and a wire was passed retrogradely from the cuboid bone through the center of the distal fragment. The graft was inserted again, and it was fixed to the proximal calcaneal fragment with the inserted pin. Additional fixation was performed with a mini-plate with angular stability if needed.

Correction of the deformity aggravated the deficit of foot extension, in most cases, it was impossible to achieve a neutral position. The Achilles tendon was elongated from the posteromedial approach, and the tendon was cut in the frontal plane. The Achilles tendon was repaired with a continuous non-absorbable suture at the neutral foot position. The paratenon was repaired with absorbable sutures.

**Postoperative management.** In the absence of complications from postoperative wounds, patients were discharged from the clinic with a below-knee removable cast with weight-bearing prohibition. Patients were followed up at 4, 8 weeks, and 6-9 months postoperatively. Immobilization with a removable plaster cast lasted 4 weeks, fol-



**Fig. 3.** Patient aged 10 years (same patient). Weight-bearing pre- and postoperative radiographs: A – left foot lateral, B – right foot lateral, antero-posterior preoperative (C) and postoperative (D)

lowed by radiography of the foot in two projections. Usually, in this period, there was a fusion of the os calcis with a graft. The full load was started in a modelled plaster cast with heel and continued for 4 weeks. During the next visit, a weight-bearing X-ray was performed in antero-posterior, lateral and Cobey's views to record radiographic findings. Progression of graft incorporation was also noted. The patient was allowed to load without restrictions.

### Results of the study and discussion

Healing of postoperative wounds in all cases was without complications. Full load without restrictions was possible after the second visit 8 weeks after surgery) in 15 cases, and in 2 cases – 10 weeks after surgery. There were no nonunion.

**Radiographic follow-up.** Hindfoot alignment was achieved in all cases. The table lists the vertical and horizontal TMA, CIA, which were measured before the operation and during the follow-up period.

The operation had a good cosmetic, radiographic and functional effect (Fig. 2 and 3).

Vertical TMA improved from an average preoperative value of 21.9° (from 9° to 37°) to an average value of 1.9° (from 0° to 19°) at follow-up. Horizontal TMA improved from an average preoperative value of 21.1° (from 10° to 36°) to an average value of 3° (from 0° to 15°) at follow-up.

There is an increase in the volume of effective extension of the foot, which was associated with the mandatory lengthening of the Achilles tendon. Improvements in foot function are registered by AOFAS and FFI, marked by a decrease in pain level (VAS). There has been a significant improvement in these indicators.

Idiopathic FF occurs in children and adolescents quite often and for the most part, it is asymptomatic. Indications for surgery are pain and disability in the absence of the effect of conservative treatment. The choice of surgery has now narrowed to arthroeresis of the subtalar joint and lengthening osteotomy of the os calcis, according to Evans–Mosca, complex multicomponent interventions are a thing of the past. Subtalar arthroeresis is a very popular technique for the correction of FF in children. A significant advantage of a subtalar arthroeresis is a minor trauma, the disadvantages are the possibility of painful dysfunction, migration of the implant and its removal, and limiting the eversion. Due to this, lengthening osteotomy of the os calcis looks more attractive, despite the greater complexity and duration, and the need for bone grafting.

Lengthening of the os calcis osteotomy in the treatment of FF in children provides a good functional result [1,3,5,8,13,15]. G.V. Viegas et al. [17] evaluated os calcis lengthening osteotomy results in 17 patients (34 feet) with a maximum follow-up period of 48 months. They used the AOFAS scale and showed a 27.76 increase from 68.59 to 85.76 points after 3 months; up to 96.35 points in terms of 8–48 months. Similar results were obtained by V. De Luna et al. [3] in 14 patients with an average follow-up period of 7 years 7 months: from 69.03 (59–78 points) to 97.44 (89–100 points). The maximum follow-up period was 12 years.

According to the systematic review of the literature (341 publications) in 2016, the results of the Evans–Mosca operation in 105 patients (167 feet) were published [11]. Most of the publications were presented by retrospective studies (level III and IV of evidence), and there was a high degree of patient satisfaction.

A. Dogan et al. [4] indicate a very positive moment of lengthening osteotomy of the os calcis – it leaves the possibility for any surgery on the foot skeleton in the future, in contrast to arthrodesis of the medial column, subtalar, and triple arthrodesis.

According to V. De Luna and others, important advantages of Evans–Mosca surgery are the preservation of

movements in the subtalar joint within physiological limits, multiplanar correction, and simple surgery [3].

When establishing indications for lengthening osteotomy of the os calcis, we use a radiographic sign that indicates a shortening of the lateral column of the foot. It consists of the location of the edge of the anterior process of the calcis behind the edge of the talus head – a kind of «calcis minus» symptom, or described by F. Bonnel et al. type III ratio of talus and calcis lengths [2]. They believe that such a relatively shortening of the os calcis may cause instability of the medial column of the foot. The positive effect of lengthening calcaneal osteotomy is manifested by the alignment of the relative lengths of talus and calcis.

Some authors use a graft from the tibia, others – iliac crest autograft as well as allografts [1,3,5,8,15]. S.A. Müller et al. compared the results of the use of auto- and allografts in the lengthening osteotomy of the os calcis and found no significant difference in terms of bony union and functional results [15]. We also did not see a significant difference in the timing of accretion when using auto- and allografts. We prefer autografting, but in cases up to 10 years, we use a scaffold from the femoral head. The main advantage of allografting is the absence of donor-site morbidity.

X-ray dynamics is evaluated by the rate of union and graft remodeling, and the change of radiographic parameters. There is no consensus in the literature on what parameters and what terms to apply them [11]. The most popular are angles: vertical and horizontal talo-1st-metatarsal, vertical and horizontal talo-calcaneal, calcaneal inclination angle, talar declination angle, talo-navicular coverage angle [11]. However, almost no one calculates all these angles, preferring a maximum of three. We use vertical and horizontal TMA, CIA. Vertical and horizontal TMA reflect, respectively, the height of the medial arch and abduction-adduction of the forefoot, CIA – its projection slope. The three-coordinate correction that occurs during the Evans operation affects the values of these three angles.

In our patients, nonunion of the lengthening calcaneal osteotomy was never observed. All radiographic parameters were improved, the difference between pre- and postoperative values was statistically significant ( $p < 0.001$ ).

It is very important to ensure a sufficient amount of foot extension during the lengthening of the os calcis osteotomy. Some authors carry out percutaneous Achilles tendon lengthening, another – open surgery [1,3,4], but everyone pays attention to the need to correct equinus. In our study, all cases were presented by FF with m. triceps surae shortening. The lengthening of the lateral

column caused an even greater restriction of the foot extension. In our cases, after the os calcis lengthening, the deficit of the effective foot extension exceeded 15°, which required an open Achilles tendon lengthening.

Our research has certain disadvantages that are inherent in all publications on the issue of lengthening the os calcis osteotomy. These shortcomings: retrospective study, small number of patients, and lack of randomization. This is indicated in systematic reviews of the literature [10,11]. On the other hand, it is likely that the lengthening of the os calcis osteotomy will continue to be a fairly exclusive operation.

## Conclusion.

Os calcis lengthening osteotomy is an effective operation in the treatment of symptomatic flexible flatfoot in children, which provides a significant reduction in pain, good clinical and radiological results. It is based on the simultaneous normalization of the geometry of the peritalar zone while maintaining movements in the hindfoot within physiological limits. An important component of the successful result of the os calcis osteotomy is to ensure sufficient foot extension, which requires lengthening of the Achilles tendon. The advantages of os calcis lengthening osteotomy are simple surgical techniques and a low risk of neurovascular complications.

*The authors declare no conflict of interest.*

## References/Література

1. Baghdadi T, Mazoochy H, Guity M, Khabbaz NH. (2018). Evaluation of clinical and radiological results of calcaneal lengthening osteotomy in pediatric idiopathic flexible flatfoot. Arch Bone Jt Surg. 6(5): 402-411. PMID: 30320181.
2. Bonnel F, Teissier P, Maestro M, Ferré B, Toullec E. (2011). Biometry of bone components in the talonavicular joint: a cadaver study. Orthop Traumatol Surg Res. 97; 6 Suppl: S66-73. doi: 10.1016/j.otsr.2011.06.005.
3. De Luna V, De Maio F, Caterini A, Marsiolo M, Petrunaro L et al. (2021). Surgical treatment of severe idiopathic flexible flatfoot by evans-mosca technique in adolescent patients: a long-term follow-up study. Adv Orthop. 20(1): 8843091. doi: 10.1155/2021/8843091.

## Відомості про авторів:

**Лябах Андрій Петрович** – д.мед.н., проф., зав. відділом патології стопи та складного протезування ДУ «Інститут травматології та ортопедії НАМН України». Адреса: м. Київ, вул. Бульварно-Кудрявська, 27; тел.: +38 (044) 486-24-87. <https://orcid.org/0000-0001-5734-2392>.

**Турчин Олена Андріївна** – д.мед.н., зав. відділенням патології стопи та складного протезування ДУ «Інститут травматології та ортопедії НАМН України». Адреса: м. Київ, вул. Бульварно-Кудрявська, 27; тел.: +38 (044) 486-26-89. <https://orcid.org/0000-0002-8668-7063>.

**Омельченко Тарас Миколайович** – д.мед.н., проф. каф. травматології та ортопедії НМУ ім. О.О. Богомольця. Адреса: м. Київ, бульв. Шевченка, 13. <https://orcid.org/0000-0003-1722-0803>.

Стаття надійшла до редакції 12.07.2025 р., прийнята до друку 12.12.2025 р.

4. Doğan A, Albayrak M, Akman YE, Zorer G. (2006). The results of calcaneal lengthening osteotomy for the treatment of flexible pes planovalgus and evaluation of alignment of the foot. Acta Orthop Traumatol Turc. 40(5): 356-366. PMID: 1722064.
5. Evans D. (1975). Calcaneo-valgus deformity. J Bone Joint Surg Br. 57(3): 270-278. PMID: 1171869.
6. García-Rodríguez A, Martín-Jiménez F, Carnero-Varo M, Gómez-Gracia E, Gómez-Aracena J, Fernández-Crehuet J. (1999). Flexible flat feet in children: a real problem? Pediatrics. 103(6): e84. doi: 10.1542/peds.103.6.e84.
7. Harris RI, Beath T. (1948). Hypermobile flat-foot with short tendo achillis. J Bone Joint Surg Am. 30: 116-140. PMID: 18921631.
8. Kim HY, Cha YH, Lee JS, Kil K-M, Choy WS. (2020). Changes in gait and radiographic and clinical results of calcaneal lengthening osteotomy in children with idiopathic flexible flatfoot. Clin Orthop Surg. 12(3): 386-395. doi: 10.4055/cios19150.
9. Kitaoka H. (1994). Clinical rating systems for the ankle – hindfoot, midfoot, hallux, and lesser toes. Foot Ankle Int. 15(7): 349-53. doi: 10.1177/107110079401500701.
10. Kumar S, Sonanis SV. (2017). Lateral column lengthening for adolescent idiopathic pes planovalgus deformity – Systematic review. J Orthop. 31; 14(4): 571-576. doi: 10.1016/j.jor.2017.07.013.
11. Lima TC, Volpon JB. (2018). Calcaneal lateral column lengthening osteotomy for symptomatic flexible flatfoot in children and adolescents: a systematic review. Rev Col Bras Cir. 45(6): e1969. doi: 10.1590/0100-6991e-20181969.
12. Martinelli N, Scotto GM, Sartorelli E, Bonifacini C, Bianchi A, Malerba F. (2014). Reliability, validity and responsiveness of the Italian version of the Foot Function Index in patients with foot and ankle diseases. Qual Life Res. 23(1): 277-284. doi: 10.1007/s11136-013-0435-4.
13. Mosca VS. (1995). Calcaneal lengthening for valgus deformity of the hindfoot. Results in children who had severe, symptomatic flatfoot and skewfoot. J Bone Joint Surg Am. 77(4): 500-512. doi: 10.2106/00004623-199504000-00002.
14. Mosca VS. (2010). Flexible flatfoot in children and adolescents. J Child Orthop. 4(2): 107-121. doi: 10.1007/s11832-010-0239-9.
15. Müller SA, Barg A, Vavken P, Valderrabano V, Müller AM. (2016). Autograft versus sterilized allograft for lateral calcaneal lengthening osteotomies: Comparison of 50 patients. Medicine (Baltimore). 95(30): e4343. doi: 10.1097/MD.0000000000004343.
16. Sangeorzan BJ, Mosca V, Hansen ST Jr. (1993). Effect of calcaneal lengthening on relationships among the hindfoot, midfoot, and forefoot. Foot Ankle. 14(3): 136-141. doi: 10.1177/107110079301400305.
17. Viegas GV. (2003). Reconstruction of the pediatric flexible planovalgus foot by using an Evans calcaneal osteotomy and augmentative medial split tibialis anterior tendon transfer. J Foot Ankle Surg. 42(4): 199-207. doi: 10.1016/s1067-2516(03)70029-5.