

UDK 616.233-003.7-002.7-007.17-053.2

S. Babuci¹, V. Petrovici², N. Dogotari², M. Efros^{1,2}

Kartagener syndrome associated with bronchopulmonary dysplasia and complicated by obstructive granulomatous bronchiolitis in children

¹State University of Medicine and Pharmacy «Nicolae Testemițanu», Chisinau, Republic of Moldova

²PMSI «Institute of Mother and Child», Chisinau, Republic of Moldova

PAEDIATRIC SURGERY.UKRAINE.2018.1(58):41-48; doi 10.15574/PS.2018.58.41

The rarity of Kartagener syndrome, as well as the presence of structural malformative changes associated with the progressive development of granulomatous bronchiolitis, was considered appropriate for the presentation of a clinical case with unfavorable prognosis.

Analyzing the clinical laboratory, diagnostic imaging and histopathological results, the authors have concluded that computed tomography data, pulmonary perfusion disturbances found at pulmonary scintigraphy along with progressive deterioration of the pulmonary ventilation function allow identifying and adequately assessing the severity of structural-functional bronchopulmonary changes in children with Kartagener syndrome. The evolution and severity of obstructive syndrome in Kartagener syndrome are determined by the development of structural changes in bronchial-alveolar peripheral airway segments, which together with interstitial inflammatory changes, progressive pneumofibrosis and development of pulmonary hypertension have unfavorable consequences on the evolution and prognosis of the disease. The coexistence of pulmonary dysplasia can be considered as an aggravating factor in the development of Kartagener syndrome in children.

Key words: Kartagener syndrome, obstructive syndrome, pneumofibrosis, pulmonary dysplasia.

Синдром Картагенера, ассоциированный с бронхолегочной дисплазией и осложненный обструктивным гранулематозным бронхиолитом у детей

С. И. Бабуч¹, В. Г. Петрович², Н. В. Доготарь², М. Ф. Эфрос^{1,2}

¹Государственный медицинский и фармацевтический университет имени Николае Тестемицану Республики Молдова, г. Кишинев

²УЗ «Институт матери и ребенка», г. Кишинев, Республика Молдова

В статье описан клинический случай редкой патологии – синдрома Картагенера у ребенка. Неблагоприятный прогноз при данном заболевании обусловлен наличием структурных мальформативных изменений, связанных с прогрессирующим развитием гранулематозного бронхиолита. Сопоставляя данные клинико-лабораторных и лучевых исследований и результаты гистопатологии, авторы пришли к выводу, что данные компьютерной томографии о нарушении легочной перфузии, обнаруженные при скинтиграфии легких, наряду с прогрессирующим ухудшением функции вентиляции легких, позволяют адекватно идентифицировать и оценить тяжесть структурно-функциональных бронхолегочных изменений у детей с синдромом Картагенера. Эволюция и тяжесть обструктивного синдрома при синдроме Картагенера определяются развитием структурных изменений в периферических бронхоальвеолярных сегментах периферических дыхательных путей, которые в сочетании с интерстициальными воспалительными изменениями, прогрессирующим пневмофиброзом и развитием легочной гипертензии имеют неблагоприятные последствия для эволюции и прогноза болезни. Наличие дисплазии легких можно рассматривать какотягающий фактор развития синдрома Картагенера у детей.

Ключевые слова: синдром Картагенера, обструктивный синдром, пневмофиброз, дисплазия легких.

Синдром Картагенера, асоційований з бронхолегеневою дисплазією та ускладнений обструктивним гранулематозним бронхіолітом у дітей

С.И. Бабуч¹, В.Г. Петрович², Н.В. Доготарь², М.Ф. Эфрос^{1,2}

¹Державний медичний і фармацевтичний університет імені Ніколає Тестемицану Республіки Молдова, м. Кишинів

²ДЗООЗ «Інститут матері і дитини», м. Кишинів, Республіка Молдова

У статті описано клінічний випадок рідкісної патології – синдрому Картагенера у дитини. Несприятливий прогноз при даному захворюванні обумовлений наявністю структурних мальформативних змін, пов'язаних з прогресуючим розвитком гранулематозного бронхіоліту. Зіставляючи дані клініко-лабораторних та променевих досліджень і результати гистопатології, автори дійшли висновку, що дані комп'ютерної томографії про порушення легеневої перфузії, виявлені при скинтиграфії легень, поряд з прогресуючим погіршенням функції вентиляції легень, дозволяють адекватно ідентифікувати та оцінити важкість структурно-функціональних бронхолегеневих змін у дітей із синдромом Картагенера. Еволюція і важкість обструктивного синдрому при синдромі Картагенера визначаються розвитком структурних змін у периферичних бронхоальвеолярних

Клінічний випадок

сигментах периферичних дихальних шляхів, які у поєднанні з інтерстиційними запальними змінами, прогресуючим пневмофіброзом і розвитком легеневої гіпертензії мають несприятливі наслідки для еволюції і прогнозу хвороби. Наявність легеневої дисплазії можна розглядати як обтяжливий чинник розвитку синдрому Картагенера у дітей.

Ключові слова: синдром Картагенера, обструктивний синдром, пневмофіброз, легенева дисплазія.

Kartagener syndrome is a rare, autosomal recessive congenital disease characterized by bronchiectasis, chronic pansinusitis and situs inversus, and is part of a broad group of conditions caused by primary ciliary dyskinesia [18,26]. Primary ciliary dyskinesia, previously known as immotile-cilia syndrome [1,29], is caused by ultrastructural defects of the cilia, resulting in the development of mucociliary dysfunction and impair-

ment of mucociliary clearance, which is one of the most important mechanisms of the respiratory tract defense [12]. The laterality of organs in embryogenesis is determined by the rotation movement of a single specialized cilium found on each of the ventral node cells defining the right-left symmetry in the developing embryo. Without a normally directed movement of this specialized cilium, the placement of organs is random, causing *situs*

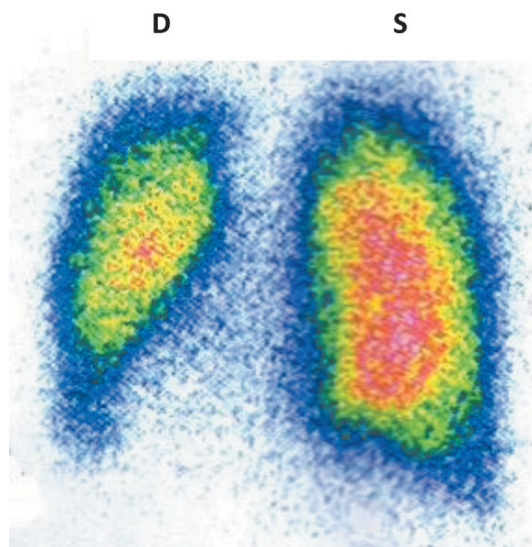


Fig. 1. Pulmonary (perfusion) scintigraphy of the *patient C.* performed in April, 2012. Diffuse decrease of pulmonary perfusion was determined in the lung located in the right hemithorax, especially in projection of the lower lobe. Dextrocardia

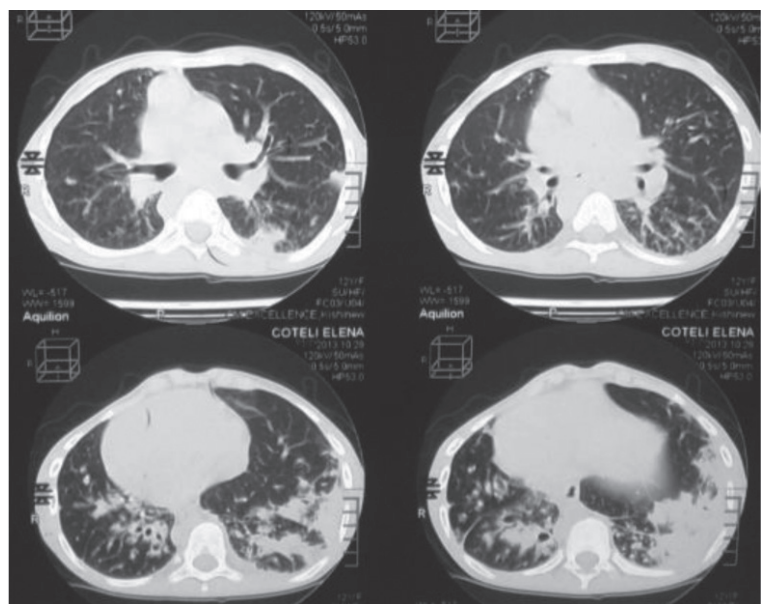


Fig. 2. Computed tomography of the *patient C.*, performed on October 29, 2013. For further explanations, see text

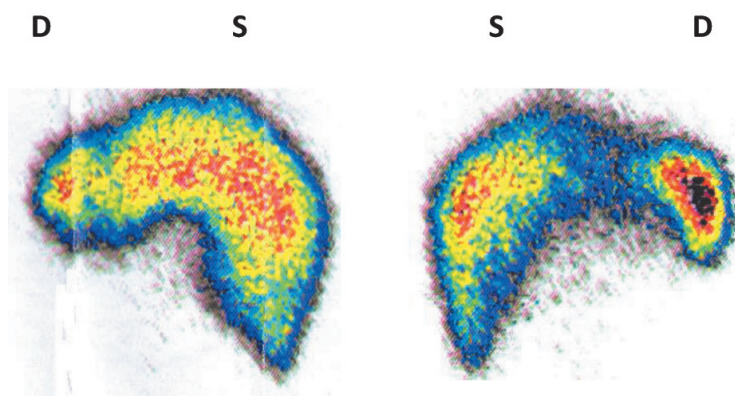


Fig. 3. Hepatic scintigraphy of the *patient C.*, performed in October, 2013. The liver positioned on the left has a regular shape and margins and is diffusely enlarged in size. There is a non-uniform distribution of the radiopharmaceutical. The spleen is of normal size, with the increased radiopharmaceutical uptake. Conclusion: Diffuse parenchymatous changes of the liver. Hepatomegaly

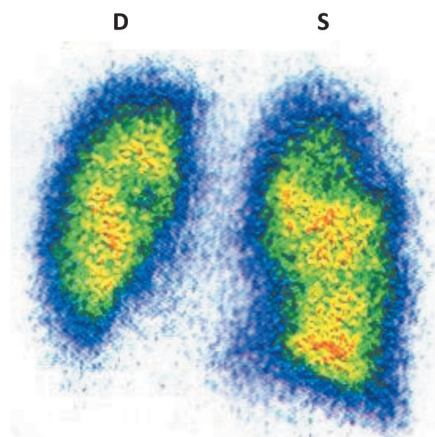


Fig. 4. Pulmonary (perfusion) scintigraphy of the *patient C.*, performed on March 26, 2014. Deformed image of both lungs with uneven distribution of the radiopharmaceutical, with small foci of diminished pulmonary perfusion over the whole pulmonary surface

inversus [28], found in over 50% of patients with primary ciliary dyskinesia [13,22].

For the first time, the classical triad, including bronchiectasis, chronic sinusitis and situs inversus, was described in 1904 by Siewert [27], although the disease was named after the Swiss pediatrician, Manes Kartagener, who described 4 cases with similar characteristics in 1933 [5,8]. In 1975, P. Camner et al. suggested ciliary dyskinesia as a cause of Kartagener syndrome [8].

B.A. Afzelius (1976) demonstrated that in patients with Kartagener syndrome the defect of ciliary motility of the respiratory mucosal epithelium in the lungs and sinuses was determined by the deficiency of the number of dynein arms, resulting in sperm motility defect in men, leading to reduced fertility [16,17].

The incidence of this genetic disease is 1–2 cases per 15,000 to 300,000 births [3,15].

Due to the rarity of this malformation, as well as the presence of some structural malformative changes associated with the progressive development of granulomatous bronchiolitis, we considered appropriate to present a clinical case with unfavorable prognosis.

The study was approved by the local ethical committee and informed consents were taken from all participants.

Patient C., aged 14 years (born September 29, 2001), was admitted to the Department of Thoraco-Abdominal Surgery of the Scientific Practical Center of Pediatric Surgery Academician Natalia Gheorghiu on November 9, 2015, with fever, dyspnea at rest and its worsening at the slightest physical effort, productive wet cough with abundant mucopurulent expectorations, nasal obstruction, marked fatigability on presentation.

The patient was ill since early childhood, being prone to respiratory diseases, including pneumonia. The patient was frequently hospitalized and followed up outpatiently by family doctors. At a young age, the patient underwent heart surgery. The medical treatment had temporary effect, providing the child's stable condition, confirmed by pulmonary perfusion scintigraphy (Fig. 1).

Since June 2013, despite the treatment, the patient's condition gradually worsened, the patient was admitted to the NSPCPS Academician Natalia Gheorghiu for an assessment of the surgical treatment necessity and possibility. On the computerized tomography, performed on October 29, 2013, there were situs inversus, the main vessels transposition, and that the lung located in the right hemithorax had 2 lobes, the contralateral one had 3 lobes. The diagnosis was established by means of imaging techniques: hypoplasia of the lower lung lobe located in the left hemithorax, cylindrical and sacciform bronchiectasis, chronic bilateral bronchopulmonary

process with signs of chronic bronchitis with bilateral pulmonary fibrosis and consolidated pneumonic foci on the left.

The transposition of internal organs was detected using the abdominal ultrasound, the hepatomegaly with diffuse parenchymatous liver modifications on the left was revealed via hepatic scintigraphy (Fig. 3). Progression of the disease was confirmed by pulmonary perfusion scintigraphy (Fig. 4).

Taking into account the anamnestic data, the clinical-evolutionary and diagnostic imaging results, after a thorough conservative treatment, on April 3, 2014 the surgical treatment was performed: right latero-posterior thoracotomy, bilobar lung pneumolysis with atypical pulmonary resection of the lower lobe. The main intraoperative difficulty was the presence of an advanced adhesion process. The postoperative course was difficult, but without complications, the patient was discharged in a satisfactory condition. Despite the surgical and conservative treatment, the scintigraphic data revealed a significant progressive decrease in pulmonary perfusion, indicating an aggravating evolution of the lung pathological process (Fig. 5).

Upon readmission of the patient to our clinic, the objective examination found the alteration of general condition, the patient had signs of malnourishment, perioral cyanosis, tachypnea (42 breaths/min) and intercostal retractions; the auxiliary muscles were involved in the respiratory process. The apical heart beats were felt by palpation inside the right midclavicular line, over the 5th intercostal space, the inferior border of the liver was palpated under the left arch of the ribs. In the laboratory tests anemia, leukocytosis with neutrophilia was detected, while liver and kidney chemistry tests were within the normal range. Spirography indicated restricted external ventilation dysfunction (grade III); severe obstructive disorders: FVC – 17%, FEV – 16%, FEV₂₅₋₇₅ – 12%, PEF – 26%, MEF₇₅ – 26%, MEF₅₀ – 8%, MEF₅ – 9%. The diffuse bilateral form of bronchiectasis, dextrocardia (Fig. 6) and bilateral frontomaxillary pansinusitis (Fig. 7) were identified using radiological examination.

The status post marginal resection of the lower lobe on the right, the diminished left hemithorax was revealed on the computed tomography (November 12, 2015). Situs inversus was confirmed, the bronchial tree was dilated, sacciform, predominantly in the lower lobes and the posterior segments with pneumofibrosis and peribronchial infiltrative changes. There were enlarged paratracheal lymph nodes (10–14 mm) as well as in the lung hilum bilaterally (Fig. 8).

The tachycardia, deviated EA to the right, signs of biventricular hypertrophy, disorders of repolarization

Клінічний випадок

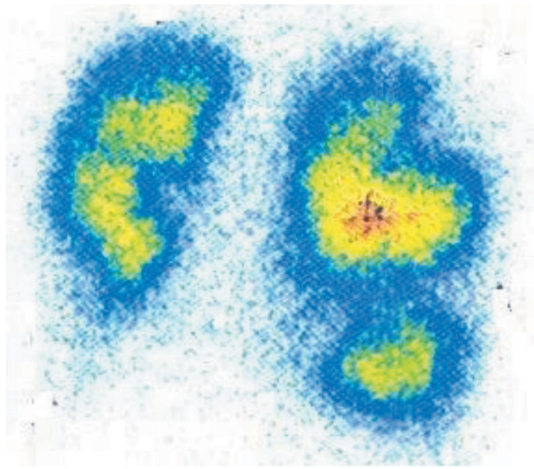


Fig. 5. Pulmonary (perfusion) scintigraphy of the *patient C.*, performed on May 15, 2015. The distorted image of both lungs is visualized. The right lung is significantly reduced in size. Non-uniform distribution of the radiopharmaceutical is determined in both lungs, with multiple foci of various sizes with decreased or no pulmonary perfusion, the pathological changes were more severe on the right

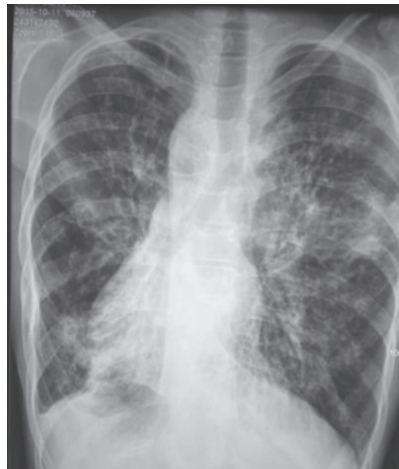

Fig. 6. *Patient C.*, 17 years old. Chest X-ray performed on admission. For further explanations, see text

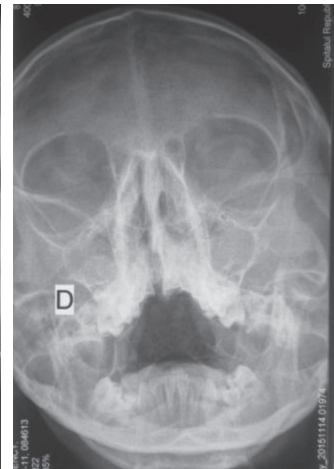

Fig. 7. *Patient C.*, 17 years old. X-ray of sinuses. For further explanations, see text

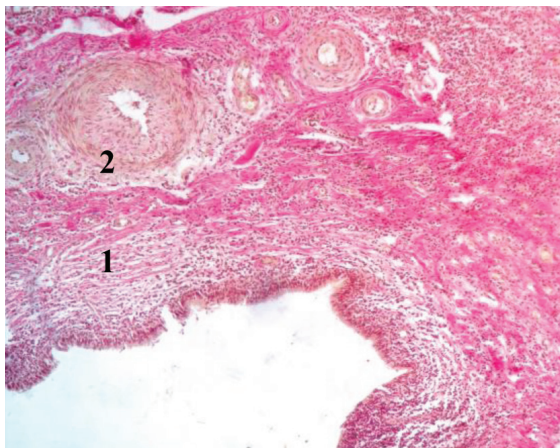


Fig. 9. The broncho-vascular segment: 1 – bronchiectatic deformity of the bronchus associated with moderate inflammatory infiltration; 2 – hypertrophic-stenosing arteriopathy with hyperelastosis. H&E staining. $\times 100$

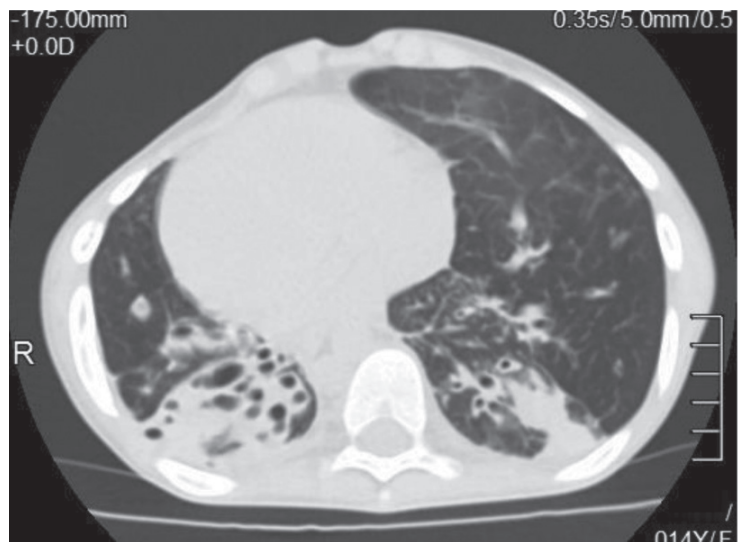

Fig. 8. Computed tomography of the *patient C.* Reversed mediastinal organs, CT signs of bilateral chronic bronchopulmonary process were visualized. Bronchiectases with more advanced changes compared to previous investigation made in 2013, especially in the lower lobes

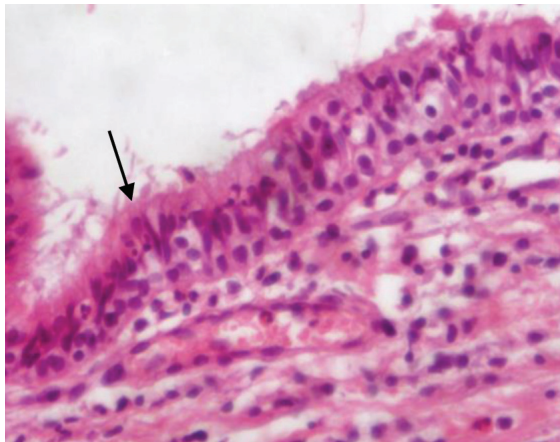


Fig. 10. Anisomorphic prismatic epithelium, partially ciliated. H & E staining. $\times 200$

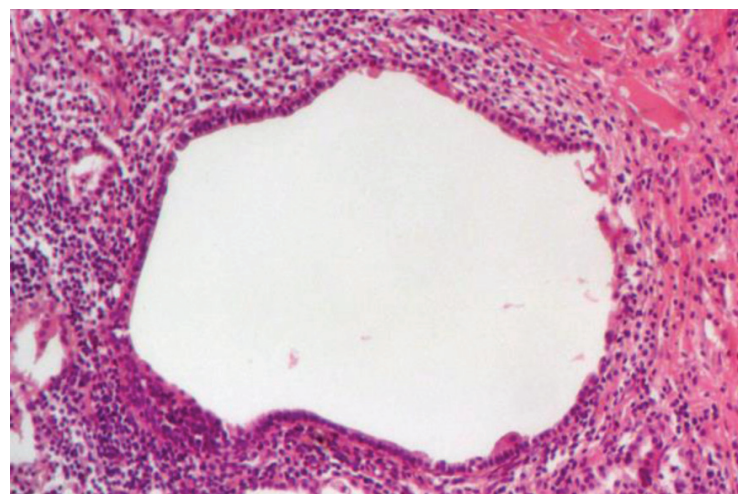


Fig. 11. Cylindrical ectatic productive bronchiolitis with unistratified flat aciliated epithelium. H&E staining. $\times 150$

processes, mitral insufficiency (grade I), tricuspid valve insufficiency (grade I), and moderate pulmonary hypertension were identified on electrocardiographic examination.

The bacteriological examination of bronchial mucus, taken during bronchoscopy, found *Streptococcus viridans*.

After a comprehensive conservative treatment, the patient's condition improved. The patient was discharged to be followed up outpatiently according to the given recommendations.

On December 14, 2015, in a very serious condition, the patient was rehospitalized in the surgical resuscitation department. The patient died on December 18, 2015.

The results of histomorphological examination, of the specimens, taken after the resection, determined both the bronchial and interstitial-alveolar involvement, with various degrees of sclerogenic reaction and inflammatory processes including dysplasia.

The changes in the bronchial tree manifested by bronchiectatic dilatations of medium caliber (segmental) bronchi, small caliber (sub-segmental) bronchi and intralobular bronchiolectasis of various forms: cylindrical, varicose and/or sacciform, often associated with a polymorphic-cellular inflammatory process, mainly lymphocytic, localized predominantly in the submucosal membrane, sometimes in the form of lymphocytic cuffs with microfocal pseudonodules. The inflammatory process was discrete or moderate in the focus, peribronchially associated with a sclerogenic reaction of varying intensity. In the areas, the bronchi had a prismatic anisomorphic and partially ciliated epithelium.

In most specimens, the bronchiectasis lumen was frequently free, with no mucous or mucopurulent discharge (Fig. 9). The epithelium of bronchiectasis, irrespective of the level of the bronchial tree, preserved the histomorphological signs of the ciliated or partially ciliated prismatic epithelium (Fig. 10), and the flat and cilia-free epithelium was observed in bronchiolectasis (Fig. 11, 12). The absence of ciliated cells in cases of primary ciliary dyskinesia and recurrent bronchitis are also described by other authors [2,6].

The alveolar structures had varying degrees of aeration from normal to hyperaeration or slightly emphysematous. The changes in the peribronchial vascular structures presented moderate hypertrophic-stenosing processes induced by hyperelastosis (Fig. 9).

In addition to these changes, in some areas there were regions with more pronounced inflammatory process of bronchi of different caliber, including bronchioles, associated with ulcerative and granulomatous obliterative

lesions, sclerogenic processes of the parenchyma with the reduction of alveolar structures (Fig. 13).

The histomorphological examination of the elastic component of the lung tissue revealed its presence at the level of the interalveolar septa and bronchioles, except for predominantly inflammatory lesions: bronchitis, bronchiolitis, and marked sclerogenic reactions with pneumosclerosis, in which null or discrete expression was found (Fig. 14).

In some areas, the interalveolar pulmonary interstitium showed discrete or moderate infiltrate with macrophages, including the wall of the ectatic terminal bronchioles with the accentuation of the connective tissue (Fig. 15). In areas with a more marked interstitial inflammatory process revealed in foci, the alveoli had a bronchial-like epithelium (Fig. 16).

The histopathological examination also determined the presence of dysplastic structures such as lobular hypoplasia, with a low alveolar index, associated with bronchiolitis and sclerogenic reactions and emphysematous areas (Fig. 17). There is parenchymal dysplasia in some areas manifested by the disorganization of structural components, bronchial-alveolar hypoplasia, pneumosclerosis, pseudocystic alveolar dysplasia, with the restructuring of the alveolar epithelium into the bronchial type, associated with a discrete and/or moderate interstitial inflammatory process. In these areas, the presence of fatty tissue in the form of vascularized pseudolobes, located in the subpleural areas (Fig. 18), could be observed.

Discussions

Kartagener syndrome is a subtype of primary ciliary dyskinesia syndrome; the affected gene is located on chromosome 15q24-25 [7]; the most frequent ciliary ultrastructural changes being dynein arms abnormalities, deficiency of radial bridges, microtubule transposition or nexin filament abnormalities [25]. There are unique studies that have found the ultrastructure of cilia within the normal range in children with Kartagener syndrome [10].

Clinical symptomatology in primary ciliary dyskinesia, including Kartagener syndrome, is quite varied, some cases occurring in the neonatal period by respiratory distress, others in later periods with signs of recurrent pneumonia, chronic productive cough, bronchiectasis, atypical non-responsive to treatment asthma, nasal polyps, chronic rhinosinusitis, hearing impairment and chronic otitis, bronchiectasis in adolescence and adulthood, chronic mucopurulent expectorations, progressive obstructive ventilatory disorders, nasal polyposis and halitosis, as well as male infertility (50%) and extrauterine pregnancy in women [24,25]. The severity of clinical evolution is de-

Клінічний випадок

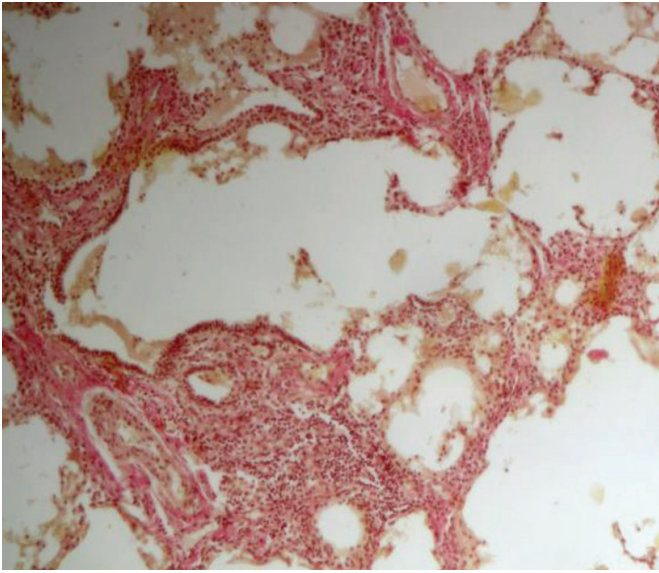


Fig. 12. Terminal bronchiolectasis lined with flat aciliated epithelium. H&E staining. x100

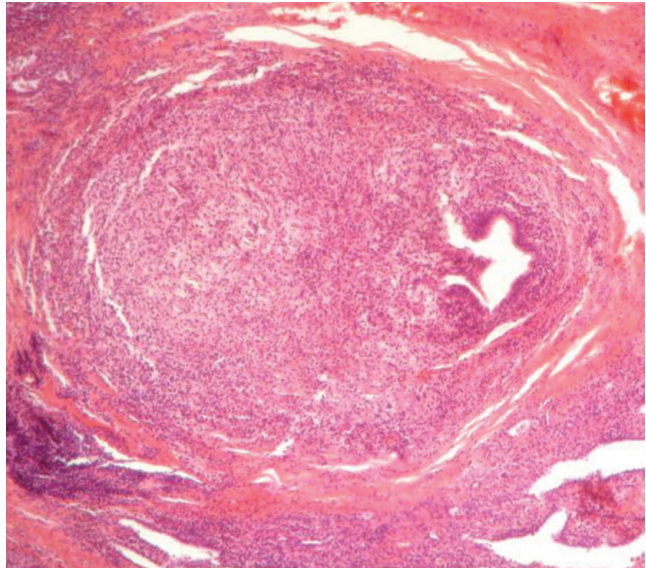


Fig. 13. Obliterative granulomatous ulcerative bronchiolitis. H&E staining. x125

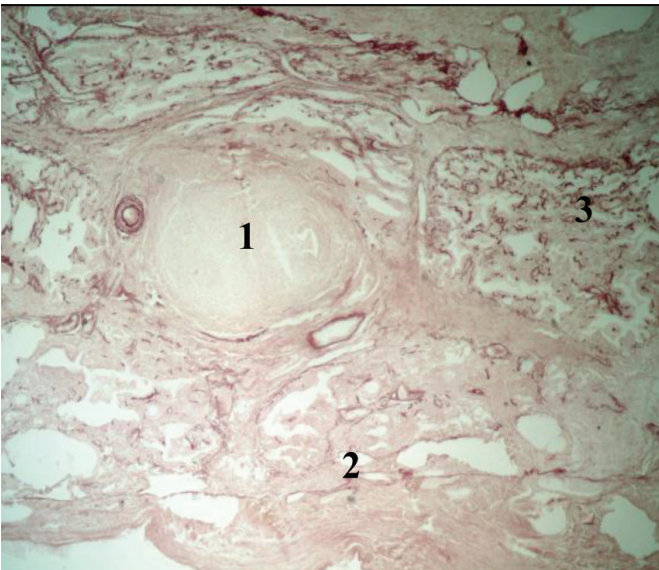


Fig. 14. Histochemical expression of elastic tissue with orcein in the broncho-vascular structure (1), pneumosclerosis area (2) and interalveolar septa. Orcein stain. x75

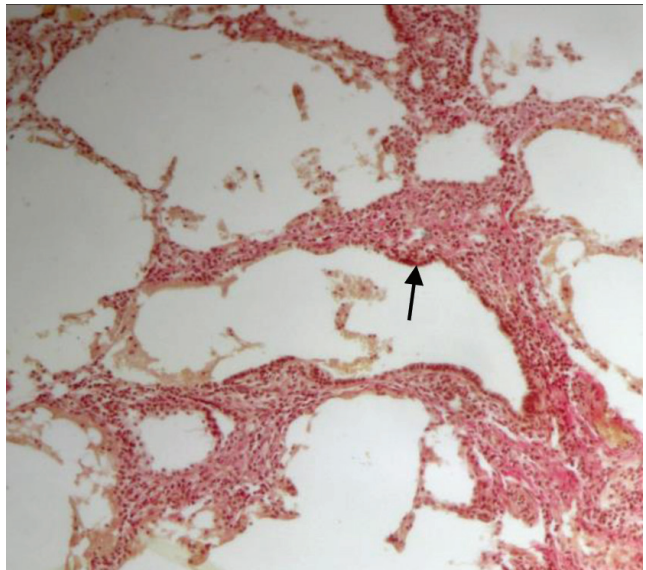


Fig. 15. Bronchiole with signs of productive bronchiolitis and bronchiolectasis. Van Gieson stain. x100

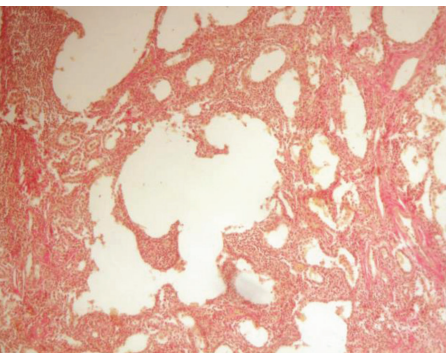


Fig. 16. Polymorpho-cellular interstitial pneumonia with alveolar epithelial restructuring into the pseudobronhiolic epithelium. Van Gieson stain. x100

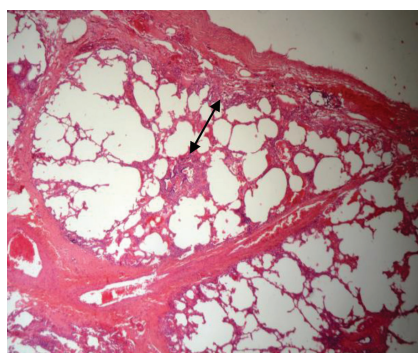


Fig. 17. Hypoplasia of pulmonary lobules with decreased alveolar index and accentuation of sclerogenic reactions over the interlobular septa. H & E staining. x75

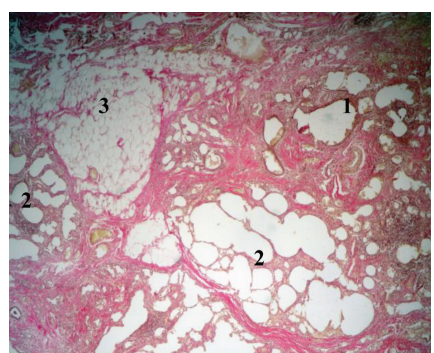


Fig. 18. Dysplasia of pulmonary parenchyma: 1 – bronchiolectasis; 2 – cystic alveolar dysplasia; 3 – fat tissue. H & E staining. x25

pendent on the number of pulmonary lobes involved and the severity of bronchiectasis development, the early diagnosis of the disease with an appropriate treatment, contributing to slow development and even preventing the onset of bronchiectasis [23].

Taking into account the results of the histopathological examination, the progressive chronic obstructive syndrome in the given case was determined by the progressive granulomatous ulcerative bronchiolitis obliterans, bronchopulmonary dysplasia as an aggravating factor. Several authors have suggested that diffuse bronchiolitis may be one of the characteristic pulmonary manifestations in primary ciliary dyskinesia syndrome and should be included in the diagnostic criteria of Kartagener syndrome [11,21]. In this context, differential diagnosis with diffuse panbronchiolitis is required, which is an idiopathic inflammatory disorder that predominantly affects respiratory bronchioles, evolving with progressive suppurative and severe obstructive pulmonary disorders [4], described for the first time by the Japanese authors [30].

Histologically, the inflammatory lesions in Kartagener syndrome affect the membranous bronchioles, while in diffuse panbronchiolitis predominantly respiratory bronchioles and adjacent central-lobular regions are affected with characteristic interstitial accumulation of foamy histiocytes, neutrophils and lymphocyte infiltration [4,19].

In our study, both types of bronchioles were significantly impaired. We assume that terminal bronchiolitis developed as a result of bronchiolitis obliterans in membranous bronchioles, having as a substrate the impairment of mucociliary clearance and secretion retention with the association and persistence of an infectious inflammatory process responsible for the structural changes of the airways with abnormal and permanent ectasia. These dysplastic processes have mixed origin both congenital, manifested by structural tissue disorganization, including the presence of fatty tissue, and secondary, such as bronchiolo-alveolar cystic dysplasia. There are few studies that have found ciliary defects associated with bronchopulmonary dysplasia [2, 14]. At the same time, the researchers have documented the development of bronchiectasis in children with bronchopulmonary dysplasia [9]. In the literature, bronchiolitis is casuistically described [20].

Conclusions

1. The computed tomography data and pulmonary perfusion disturbances found at pulmonary scintigraphy along with the progressive deterioration of the pulmonary ventilation function allow adequately identifying and as-

sessing the severity of structural-functional bronchopulmonary changes in children with Kartagener syndrome.

2. The evolution and severity of obstructive syndrome in patients with Kartagener syndrome are determined by the development of structural changes in broncho-alveolar peripheral airway segments, which together with interstitial inflammatory changes, progressive pneumofibrosis and pulmonary hypertension, have unfavorable consequences on the evolution and prognosis of the disease.

3. The coexistence of pulmonary dysplasia may be considered as an aggravating factor in the development of Kartagener syndrome in children.

No conflict of interest was declared by the authors.

References

1. Afzelius B.A. (1998). Immotile cilia syndrome: past, present, and prospects for the future. *Thorax*. 53: 894–7.
2. Biczysko W., Marszalek A., Seget M. et al. (2003). Changes in the bronchial epithelia in patient with immotile cilia syndromes. *Folia Morphol.* 62(4): 393–5.
3. Bush A., Chodhari R., Collins N. et al. (2007). Primary ciliary dyskinesia: current state of the art. *Arch. Dis. Child.* 92: 1136–40.
4. Chen W., Shao C., Song Y., Bai C. (2014). Primary ciliary dyskinesia complicated with diffuse panbronchiolitis: a case report and literature review. *Clin. Respir. J.* 8: 425–30.
5. Dabhi A.S., Chaudhari S.R., Thorat P.B. et al. (2005). Kartagener's syndrome: a triad of bronchiectasis, situs inversus, and chronic sinusitis. *J. IACM.* 6(3): 241–3.
6. Gaillard D., Jouet J.B., Rgretau L. et al. (1994). Airway epithelial damage and inflammation in children with recurrent bronchitis. *Am. J. Respir. Crit. Care Med.* 150: 810–7.
7. Geremek M., Zietkiewicz E., Diehl S.R. et al. (2006). Linkage analysis localises a Kartagener syndrome gene to a 3.5 cM region on chromosome 15q24–25. *J. Med. Genet.* 43(1): e1.
8. Gupta S., Handa K.K., Kasliwal R.R., Bajpai P. (2013). A case of Kartagener's syndrome: Importance of early diagnosis and treatment. *Indian J. Hum. Genet.* 19: 266–9.
9. Hayes D., Kriss V.M., Iocono J.A. et al. (2009). Varicose bronchiectasis and bronchopulmonary dysplasia. *Respir. Care.* 54(11): 1493–5.
10. Herzon F.S., Murphy S. (1980). Normal ciliary ultrastructure in children with Kartagener's syndrome. *Ann. Otol. Rhinol. Laryngol.* 89; 1; Pt 1: 81–3.
11. Homma S., Kawabata M., Kishi K. et al. (1999). Bronchiolitis in Kartagener's syndrome. *Eur. Respir. J.* 14: 1332–9.
12. Kim J.H., Song W.J., Jun J.E. et al. (2014). Mycobacterium abscessus lung disease in a patient with Kartagener's syndrome. *Tuberc. Respir. Dis.* 77: 136–40.
13. Knowles M.R., Daniels L.A., Davis S.D. et al. (2013). Primary ciliary dyskinesia. Recent advances in diagnostics, genetics, and characterization of clinical disease. *Am. J. Respir. Crit. Care Med.* 188: 913–22.
14. Lee R.M., Rossman C.M., O'Brodovich H. et al. (1984). Ciliary defects associated with the development of bronchopulmonary dysplasia. Ciliary motility and ultrastructure. *Am. Rev. Respir. Dis.* 129(1): 190–3.
15. Leigh M.W., Pittman J.E., Carson J.L. et al. (2009). Clinical and genetic aspects of primary ciliary dyskinesia / Kartagener syndrome. *Genet. Med.* 11(7): 473–87.
16. Lobo L.J., Zariwala M.A., Noone P.G. (2014). Primary ciliary dyskinesia. *Q. J. Med.* 107: 691–9.
17. McManus I.C., Mitchison H.M., Chung E.M. K. et al. (2003).

Клінічний випадок

- Primary ciliary dyskinesia (Siewert's/Kartagener's syndrome): respiratory symptoms and psycho-social impact. BMC Pulm. Med. 3: 4.
- Mishra M., Kumar N., Jaiswal A. et al. (2012). Kartagener's syndrome: A case series. Lung India. 29: 366–9.
 - Mittal V., Shah A. (2012). Situs inversus totalis: the association of Kartagener's syndrome with diffuse bronchiolitis and asospermia. Arch. Bronconeumol. 48(5): 179–82.
 - Nonomura A., Mizukami Y., Murakami S. et al. (1993). Abscessing bronchioloectasia with elements of plasma cell granuloma. Intern. Med. 32(10): 821–3.
 - Ozkaya S., Sahin U., Gumus A. et al. (2011). Bronchiolitis as a feature of Kartagener syndrome: a case report. J. Bronchology Interv. Pulmonol. 18: 88–90.
 - Pandey A.K., Maithani T., Bhardwaj A. (2014). Kartagener's syndrome: A clinical reappraisal with two case reports. Egyptian J. Ear, Nose, Throat and Allied Sci. 15: 171–4.
 - Pappas K., Pentheroudaki A., Ferdoutsis E. et al. (2011). Bronchiectasis in congenital diseases: pathogenesis, imaging, diagnostic approach. Pneumon. 24(3): 248–62.
 - Ribeiro J.D., Fischer G.B. (2015). Chronic obstructive pulmonary disease in children. J. Pediatr. (Rio J.). 91; 6; Suppl 1: 11–25.
 - Rugină A.-L., Dimitriu A.G., Nistor N. et al. (2014). Primary ciliary dyskinesia diagnosed by electron microscopy in one case of Kartagener syndrome. Rom. J. Morphol. Embryol. 55; 2; Suppl: 697–701.
 - Serapinas D., Staikuniene J., Barkauskiene D. et al. (2013). An unusual regression of the symptoms of Kartagener's syndrome. Arch. Bronconeumol. 49(1): 28–30.
 - Siewert A. (1904). Uber einen Fall von Bronchiektasie bei einem Patientem mit Situs inversus viscerum. Berlin Klin Wochenschr 41: 139–41.
 - Tilley A.E., Walters M.S., Shaykhiev R., Crystal R.G. (2015). Cilia dysfunction in lung disease. Ann. Rev. Physiol. 77: 379–406.
 - Whitelaw A., Evans A., Corrin B. (1981). Immobile cilia syndrome: a new cause of neonatal respiratory distress. Arch. Dis. Child. 56: 432–5.
 - Yamanaka A., Saiki S., Tamura S., Saito K. (1969). Problems in chronic obstructive bronchial diseases, with special reference to diffuse panbronchiolitis. Naika. 23: 442–51.

Відомості про авторів:

S. Babuci – dr.hab.med., Leading Researcher, University of Medicine and Pharmacy «Nicolae Testemitanu», Department of Pediatric Surgery, Orthopedics and Anesthesiology, Surgical Infection Laboratory, Republic of Moldova, MD-2004, Chisinau, Stefan cel Mare, 165.

V. Petrovici – dr.med., senior scientific researcher, chef of morphopathology PMSI Mother and Child Institute, Chisinau, Republic of Moldova, st. Burebista, 93.

N. Dogotari – scientific researcher in Laboratory for Surgical Correction of Congenital Anomalies in Children, PMSI Mother and Child Institute, Chisinau, Republic of Moldova, st. Burebista, 93.

M. Efros – assistant at the chair of radiology and imagistics at University of Medicine and Pharmacy «Nicolae Testemitanu», Department of Radiology and Imagistics; PMSI Mother and Child Institute, Radiology And Imagistics Section, Chisinau, Republic of Moldova, st. Burebista, 93.

Стаття надійшла до редакції 18.09.2017 р.

XXIV З'ЇЗД ХІРУРГІВ УКРАЇНИ, ПРИСВЯЧЕНИЙ 100-РІЧЧЮ З ДНЯ НАРОДЖЕННЯ АКАДЕМІКА О.О. ШАЛІМОВА

26-28 вересня 2018 року

м. Київ

Організатори: ДУ «Національний інститут хірургії та трансплантології імені О.О.Шалімова» НАМН України, ГО «Асоціація хірургів України»

Основні програмні питання з'їзду

- Хірургічне лікування бойових ушкоджень, їх ускладнень та наслідків.
- Проблеми абдомінальної, торакальної та судинної хірургії.
- Проблеми ургентної хірургії.
- Ускладнення в хірургії.
- Перитоніт, сепсис та інфекції, пов'язані з наданням медичної допомоги.
- Хірургія ендокринних органів.
- Хірургія серця.
- Дитяча хірургія.
- Трансплантація органів.
- Мікросудинна та пластична хірургія.
- Експериментальна хірургія.

Веб-сторінка конференції: <http://as-ukr.org/informatsijne-povidomlennya/>