

UDK 616.62-003.7-055.23-036.65-089

E. Wajszczuk¹, M. Szymanek-Szwed¹, J. Samotyjek¹, K. Jobs², B. Jurkiewicz¹

Urolithiasis – a chronic and recurrent disease in a girl with multiple congenital anomalies and cerebral palsy – case report

¹Centre of Postgraduate Medical Education, Dziekanów, Warsaw, Poland²Military Medical Institute, Warsaw, Poland

Paediatric surgery.Ukraine.2019.3(64):37-41; doi 10.15574/PS.2019.64.37

For citation: Wajszczuk E, Szymanek-Szwed M, Samotyjek J, Jobs K et al. (2019). Urolithiasis – a chronic and recurrent disease in a girl with multiple congenital anomalies and cerebral palsy: case report. Paediatric surgery.Ukraine. 3(64): 37-41. doi 10.15574/PS.2019.64.37

Urolithiasis is a disease unit more common in adult patients. However in the pediatric population it is also an important clinical problem due to high risk of recurrence in the patient's life among others. Hypercalciuria, hyperuricemia, hyperoxaluria and cystinuria secondary to metabolic disorders promote stone formation.

The aim of this study is the presentation of a case of a girl with multiple congenital anomalies, bilateral staghorn urolithiasis and bladder stones developing in the course of hypercalcemia.

The patient was diagnosed with urolithiasis at the age of 2 months. The course of the disease in her case is characterized by extremely frequent recurrences and numerous urinary tract infections of various aetiology, including high-resistant bacterial strains. These infections were often turbulent and required hospitalization. Due to the extent of urolithiasis, invasive treatment was necessary, both in the lower and upper urinary tract. Endoscopic techniques (transurethral cystolithotripsy and ureterorenoscopy) were used in urinary bladder and ureter urolithiasis. Renal deposits were removed by the use of open access surgery (pyelolithotomy with intrarenal lithotripsy).

Although the ongoing development technology and miniaturization of equipment have allowed and popularized minimally invasive treatment of urolithiasis, some exceptional cases still require surgical treatment with open surgery.

The research was carried out in accordance with the principles of the Helsinki Declaration. The study protocol was approved by the Local Ethics Committee (LEC) of all institutions.

No conflict of interest was declared by the authors.

Key words: urolithiasis, children, recurrence, surgical treatment.

Сечокам'яна хвороба – хронічна та рецидивна хвороба у дівчинки з множинними вродженими аномаліями та церебральним паралічем: клінічний випадок

E. Wajszczuk¹, M. Szymanek-Szwed¹, J. Samotyjek¹, K. Jobs², B. Jurkiewicz¹¹Центр післядипломної медичної освіти, Дзеканув, м. Варшава, Польща²Військово-медичний інститут, м. Варшава, Польща

Сечокам'яна хвороба – це захворювання, яке частіше зустрічається у дорослих пацієнтів. Однак у педіатричній практиці вона також є важливою клінічною проблемою через високий ризик рецидивів протягом життя. Гіперкальціурія, гіперурикемія, гіпероксалурія та цистинурія, вторинні по відношенню до порушень обміну речовин, сприяють утворенню каменів.

Метою даного дослідження було показати особливості перебігу двосторонньої стагхорн-сечокам'яної хвороби з каменями сечового міхура, що розвиваються у процесі гіперкальціємії, у дівчинки з множинними вродженими аномаліями.

Діагноз сечокам'яної хвороби дитині був встановлений у віці двох місяців. Перебіг захворювання у даному випадку характеризувався надзвичайно частими рецидивами і численними інфекціями сечовивідних шляхів різної етіології, у тому числі з високою стійкістю бактеріальних штамів. Важкий перебіг інфекцій часто потребував госпіталізації. Дитині було необхідне інвазивне лікування сечокам'яної хвороби, як у нижніх, так і у верхніх сечовивідних шляхах. У сечовому міхурі та при уролітіазі сечоводу застосовувалися ендоскопічні методики (трансуретральна цистолітотрипсія та уретерореноскопія). Ниркові відкладення видаляли за допомогою операції відкритого доступу (пієлолітомія з внутрішньонирковою літотрипсією). Незважаючи на невпинний розвиток технологій та мініатюризацію обладнання, що уможливили і популяризували мініінвазивне лікування сечокам'яної хвороби, окремі випадки все ж таки вимагають хірургічного втручання відкритим доступом.

Дослідження виконані відповідно до принципів Гельсінської Декларації. Протокол дослідження ухвалений Локальним етичним комітетом (ЛЕК) усіх установ. На проведення досліджень було отримано поінформовану згоду батьків дитини.

Автори заявляють про відсутність конфлікту інтересів.

Ключові слова: сечокам'яна хвороба, діти, рецидив, хірургічне лікування.

Клінічний випадок

Мочекаменная болезнь – хроническое и рецидивное заболевание у девочки с множественными врожденными аномалиями и церебральным параличом: клинический случай

E. Wajszczuk¹, M. Szymanek-Szwed¹, J. Samotyjek¹, K. Jobs², B. Jurkiewicz¹

¹Центр последипломного медицинского образования, Дзеканув, г. Варшава, Польша

²Военно-медицинский институт, г. Варшава, Польша

Мочекаменная болезнь – это заболевание, которое чаще встречается у взрослых пациентов. Однако в педиатрической практике она также является важной клинической проблемой вследствие высокого риска рецидивов в течение жизни. Гиперкальциурия, гиперурикемия, гипероксалурия и цистинурия, которые вторичны по отношению к нарушениям обмена веществ, способствуют образованию камней.

Целью данного исследования было показать особенности течения двусторонней стагхорн-мочекаменной болезни с камнями мочевого пузыря, развивающимися в процессе гиперкальциемии, у девочки с множественными врожденными аномалиями.

Диагноз мочекаменной болезни поставлен ребенку в возрасте двух месяцев. Течение заболевания характеризовалось необычайно частыми рецидивами и многочисленными инфекциями мочевыводящих путей различной этиологии, в том числе с высокой стойкостью бактериальных штаммов. Тяжелое течение инфекций требовало частых госпитализаций. Ребенку было необходимо инвазивное лечение мочекаменной болезни, как в нижних, так и в верхних мочевыводящих путях. В мочевом пузыре и при уролитиазе мочеточника применялись эндоскопические методики (трансуретральная цистолитотрипсия и уретерореноскопия). Почечные отложения удаляли путем операции открытого доступа (пиелолитомия с внутрипочечной литотрипсией).

Несмотря на непрерывное развитие технологий и миниатюризацию оборудования, сделавших возможным и популяризовавших миниинвазивное лечение мочекаменной болезни, отдельные случаи все же требуют хирургического вмешательства открытым доступом.

Исследование было выполнено в соответствии с принципами Хельсинкской Декларации. Протокол исследования был одобрен Локальным этическим комитетом (ЛЭК) всех учреждений. На проведение исследований было получено информированное согласие родителей ребенка.

Авторы заявляют об отсутствии конфликта интересов.

Ключевые слова: мочекаменная болезнь, дети, рецидив, хирургическое лечение.

Introduction

Urolithiasis is a disease unit first described in antiquity. First notes on symptoms and treatment found in the Erbs Papyrus come from Egypt and are dated at 1550 B.C. Ancient Greeks possessed knowledge of transperineal stones removal from the urinary bladder. In ancient Rome a special group of «lithotomists» arose, to whom Hippocrates refers to in his oath: «I will not use the knife, not even, verily, on suffers from stone, but I will give place to such as are craftsmen therein».

Urolithiasis is one of the civilization diseases. In the last two decades a considerable morbidity increase has been observed [2,3], including pediatric population [3,4]. Recurrence is affecting 6.5-50% of patients in five year period, and is even higher in high-risk groups. Early onset of urolithiasis is one of risk factors [5]. With long life expectancy there is a great chance of recurrence over the lifetime. Moreover, stone disease and related disorders (especially urinary tract infections) can lead to physical growth retardation [4].

Formation of stones contributes to the imbalance between crystallization inhibitors and potentially crystallizing substances. This imbalance can be caused by abnormal diet, metabolic disorders, urinary retention and changes of urine pH caused inter alia by infections [6,7].

About 70% of patients suffering from kidney colic can expel the stone spontaneously, remaining 30% require medical procedures [8]. Thanks to the progress in the fields of technology, anaesthesiology and surgery, minimally invasive procedures are now performed. These are:

- Extracorporeal Shock Wave Lithotripsy (ESWL),
- Percutaneous nephrolithotripsy (PCNL),
- Ureterorenoscopic lithotripsy (URSL),
- Retrograde intrarenal surgery (RIRS).

Objective

The aim of this study is to present the medical history of a child with multiple congenital abnormalities, cerebral palsy and urolithiasis in course of hypercalcaemia, directing the reader's attention towards the disease course with extremely frequent recurrences and urinary tract infections, as well as to show possible ways of surgical treatment.

Case report

A seven year old girl, born at 40th Hbd, Apgar 10 points, hypotrophic (2500g, 50cm), with features of dysmorphia: hypotelorism, micrognathia, low-set ears, preauricular outgrowths, vaginal polyp, gothic palate. Significant family history: father with urolithiasis, sister with bilateral V grade vesicoureteral reflux, brother with hypospadias. Abdominal ultrasound was performed at the Neonatal unit and showed no anatomical defects. However, attention was paid to the hyperechogenic renal pyramids and suspicion of irregular uric concretions. The girl was discharged home in good general condition on the 7th day of life, further outpatient control was recommended.

At the age of 2.5 months the girl was admitted to hospital due to lack of weight gain. Physical examination revealed dehydration and cachexia. Laboratory tests showed the following:

- Hypercalcaemia (2.74; 2.9 mmol/l; N: 2.2-2.6 mmol/l)
- slightly increased Vit. D3 level in blood serum (124 pg/ml; N: 40-100 pg/ml) (the child was given vit. D supplementation despite lack of weight gain)
- normal inflammatory indicators
- In the abdominal USG
- Right kidney (RK): slight urinary obstruction and calyxial wall thickening and 7 mm concretions in bottom calyces

- Left kidney (LK): urinary obstruction and calyctal widening up to 4 mm.

Urinary tract infection was not found, but numerous calcium oxalates were present. After general condition improvement and weight gain, the girl was discharged with the recommendation for the extension of scheduled diagnostic and recommended to stop vit. D supplementation.

Voiding cystourethrography was performed at the age of 4 months, bilateral vesicoureteral reflux was found – II grade on the right, III grade on the left side. The procedure was further complicated with *E. Coli* and *P. Aeruginosa* urinary tract infection, treated successfully with Cefotaxime. Following renal scintigraphy showed good renal function, postinflammatory changes in the left kidney, bilateral discrete pyelocalyceal system and ureters dilatation, efficient urine output, ERPF % LK 46%, RK 54%. During hospitalisation a urinary tract infection developed caused by *P. Aeruginosa*. It was treated with Cefazidime according to the antibiogram.

Urodynamics showed: decreased bladder capacity, detrusor hyperreactivity, and increased bladder sensation. No bladder outlet obstruction was found. Oxybutynin treatment was administered at a dose of 1 mg twice daily. Detrusor areflexia was observed in a control examination after 4 months. Neurogenic bladder was diagnosed. Oxybutynin treatment was continued, intermittent catheterization was initiated and performed every 3 hours with nocturnal interruption.

Because of dysmorphia, hypercalcaemia and substantial development delay, the patient underwent genetic examinations, but no known genetic disorders were found. The cytogenetics showed normal female karyotype 46XY. She was also subjected to metabolic (calcium borderline values only), endocrinological (no abnormalities), ophthalmological (blindness), laryngological (considerable hearing impairment), and neurological diagnostics (NMR: hyperintensive zones in periventricular parietal and occipital white matter, slightly delayed brain white matter myelination, ventricular dilatation, flat liquid collections within anterior temporal regions). Intensive rehabilitation was conducted.

Abdominal ultrasonography in the second year of life revealed bilateral staghorn urolithiasis and numerous small bladder stones (calcium oxalates), cystolithotripsy was performed (Fig. 1 a, b, c).

The girl was qualified for metabolic diagnostics, performed at the Department of Pediatrics and Nephrology at the Military Medical Institute. Hypercalcaemia (2.79 mmol/l) with a low level of vit. D concentration (17.7 ng/ml; N 20-50 ng/ml) was diagnosed. The parathormone was in the range of norm (18.7 pg/ml;

N 17.3-72.9 pg/ml). 24-hour urine collection was never possible to obtain because of constant infectious changes. But a sample of spontaneously excreted calculi showed that it was a calcium oxalate urolithiasis. Appropriate treatment was implemented. An elimination diet with a large supply of fluids was prescribed to reduce the possibility of new deposits formation.

During the following 6 months the girl was hospitalised 8 times due to urinary tract infections of different bacterial aetiology: *E. Coli*, *K. Pneumoniae*, *P. Aeruginosa*, *K. Oxytoca* ESBL(+), *C. Albicans* and severe course (temperature up to 39°C, vomiting, lack of appetite). Targeted antibiotic therapy was performed resulting in gradual normalisation of inflammatory indicators.

During the next hospitalisation at the paediatric ward the patient (aged almost 3) was diagnosed with right pyonephrosis caused by a stone wedged at the level of the pelviureteric junction. The patient was transferred to the Paediatric Surgery Unit, where, after administering Imipenem, DJ catheter was inserted into the right kidney (Fig.2). After normalisation of inflammatory indicators in blood serum, the patient was qualified for surgery (open pyelolithotomy with endorenal lithotripsy). The procedure was performed 3 weeks after DJ catheter insertion with continuation of Imipenem. During the operation, on top of numerous large stones in pyelocalyceal system (Fig.3), Randall platelets were also found (Fig.4).

Postoperative abdominal USG showed total clearance of stones. However 6 months later already 4 overlapping calcifications, of 1 cm in diameter were found in the same kidney.

Seven months after the first operation, the second surgery was performed on the left side, similar to the right side – pyelolithotomy with endoscopic pyelocalyceal system lithotripsy. RIRS procedure failed because of the diameter of the ureter being too narrow. Control USG showed no renal concretions.

Over the next two years the rate of urinary tract infection recurrence was significantly lower. But in the fifth year of life it increased again. Urinary tract ultrasonography revealed bilateral staghorn urolithiasis recurrence. Numerous stones were found in the right kidney, the largest one with dimensions 25x19x11.2 mm, calyctal dilation to 20.4 mm, cortical thinning to 6.4 mm and staghorn stones in the left kidney, measuring 18.7x15.3x11.2 mm, and parenchymal cortex thickness 9.1 mm. An X-ray additionally showed a stone in the distal ureter on the right side (Fig.5).

In the sixth year of life a right-side pyelolithotomy, preceded by ureterorenoscopy, was performed. A total clearance of stones was achieved. The procedure was

Клінічний випадок

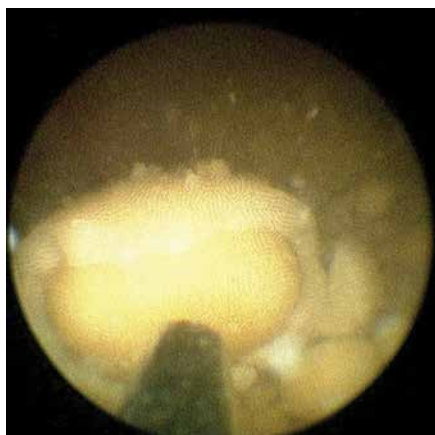

Fig. 1a. Cystolotripsy – visible stone in the initial phase of crushing

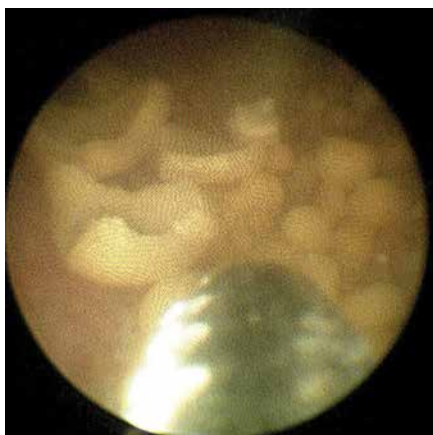


Fig. 1b. Cystolotripsy – crushed concretions

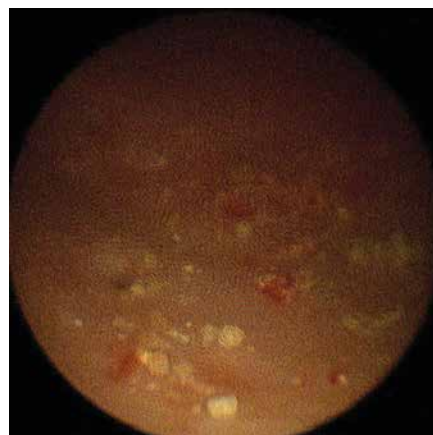

Fig. 1c. Urinary bladder – state after removal of the deposits

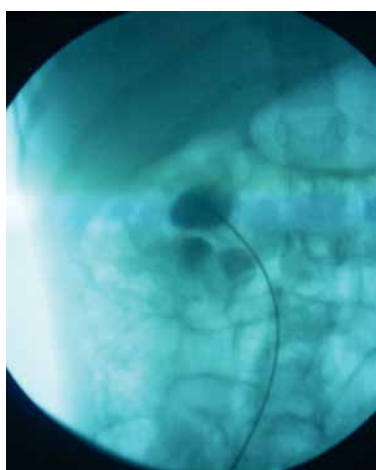


Fig. 2. Ascending pyelography – visible deposits in the right kidney and a DJ catheter decompressing the pyelocalyceal system

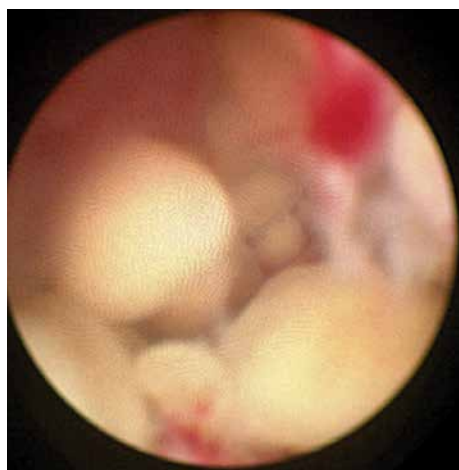


Fig. 3. Intraoperative picture – visible numerous deposits in calyces

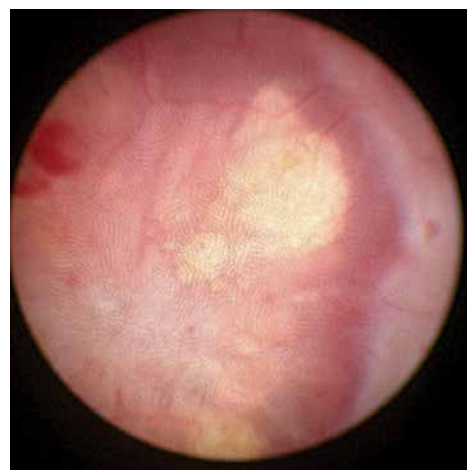

Fig. 4. Intraoperative picture – Randall platelets

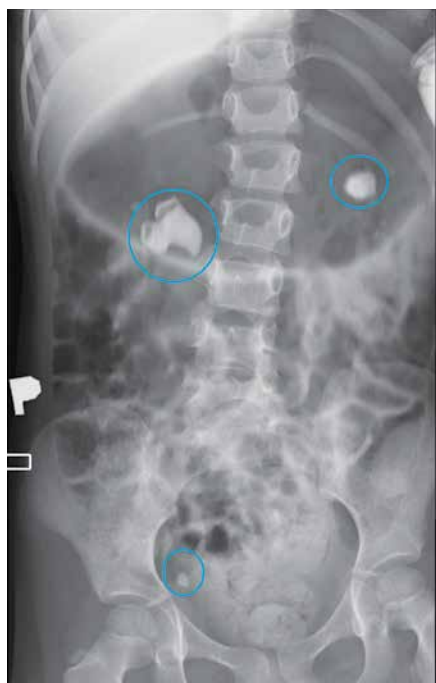

Fig. 5. X-ray – abdominal view

complicated with systemic infection. With targeted Meropenem antibiotic therapy and DJ catheter removal, improvement of the general condition and normalization of inflammatory markers have been achieved. A month after the discharge, after another episode of UTI requiring Meropenem treatment (*K. Oxytoca* sensitive only to carbapenems was cultured in urine), the girl was qualified for the left-sided pyelolithotomy. In spite of left kidney concretions described in ultrasonography and visualized on X-ray scans, all visible calcified lesions intraoperatively were found to be submucosal. The left kidney DJ catheter was left. The postoperative course was uncomplicated and the girl was discharged home 2 weeks after the surgery, after the DJ catheter removal.

The girl is in ambulatory care. She has been treated for recurrent urinary tract infections. Deposits collecting in the bladder are removed by endoscopies. Due to urolithiasis and urinary tract infections, she has been hospitalized 26 times.

Results

Urolithiasis is a diversified disease. It may affect the elderly as well as young children. Symptoms vary from microscopic hematuria to a renal colic with vomiting and fever and may lead to urosepsis. Most patients experience only one episode in their life, but early onset is one of risk factors for recurrence. Others are metabolic and genetic disorders, anatomical abnormalities and familial history. Each of these factors applies to our patient. The patient's lying lifestyle is an additional factor contributing to the formation of stones (the girl does not move or sit on her own). That altogether leads to an extremely recurrent course of disease with UTIs of severe course. The calculi were treated accordingly to their position in the urinary tract. Bladder stones with cystolithotripsy, uretral with URSL, renal staghorn stones with open pyelolithotomy combined with endoscopic lithotripsy. One attempt of RIRS failed due to the size of ureter.

These methods help preserving renal function as well as diminish the UTI's rate.

Discussion

Stone disease is a pathology known and treated since antiquity. Its prevalence is rising and it is gaining the status of civilization disease. It is affecting mainly adults, but the incidence in children is constantly rising and reaching now 1-2% [3,9]. The actual numbers may be even higher, as it is believed to be underdiagnosed.

Clinical manifestations include abdominal pain, renal colic, urinary infection, hematuria, vomiting, urinary symptoms, fever, nausea and others [10]. The recurrence rate in children is very high ranging from 20 to 50% according to different studies [3,9,10]. Risk factors for developing urolithiasis are: metabolic disorders leading to a high exertion of urine crystalization factors into urine; anatomical abnormalities affecting the right urine flow (eg. ureteropelvic junction obstruction, uretral stricture, vesico-uretero-renal reflux, ureterocele, etc.), genetic disorders, urinary tract infections, obesity and others.

The treatment should target clearance of stones, treatment of UTIs, preservation of kidney function and recurrence prevention.

The majority of patients are able to pass the stones without surgical intervention, however it is needed in approximately 30% of cases. Technological development and miniaturisation of equipment enabled the procedure to be minimally invasive. The endourology and ESWL have pushed open and laparoscopic procedures into secondary position, leaving them for the most complicated cases [11,12]. Open pyelolithotomy with endoscopic stone disintegration is one of these procedures. It enables total clearance of stones without damage to renal parenchyma [13].

Unfortunately no surgical treatment is able to suppress stone formation that progresses extremely rapidly in this patient.

Perhaps new trials on urolithiasis genesis in genetics, endocrinology and microbiology will allow to do that.

References/Література

- Lewandowska M., Sybilski AJ. (2013). History of urolithiasis therapy. *Prob. Lek.* 49(1/2): 88-90.
- Sas DJ, Hulsey TC, Shatat IF, Orak JK. (2010, Jul). Increasing incidence of kidney stones in children evaluated in the emergency department. *J Pediatr.* 157(1): 132-7. doi: 10.1016/j.jpeds.2010.02.004. Epub 2010 Apr 1.
- Chen JN, Dieguez LM, Trachtman H. (2014). The Changing Epidemiology of Urolithiasis in Pediatric Patients. *J Nephrol Therapeutic.* S11: S11-006. doi:10.4172/2161-0959.S11-006
- Van Dervoort K et al. (2007). Urolithiasis in Pediatric Patients: A Single Center Study of Incidence, Clinical Presentation and Outcome. *J Urol.* 177(6): 2300-2305.
- Turk C (Chair), Knoll T (Vice-chair), Petrik A, Sarica K, Skolarikos A, Straub M, Seitz C. (2015). Guidelines on urolithiasis, EAU.
- Jung A. (1995). Urolithiasis threat, prevention and treatment of urinary stones in children, Agama s.c., Warszawa.
- Gadoska-Prokop K. (2007). Leczenie zachowawcze kamicy układu moczowego. *Przegląd Urologiczny.* 2007/3(43).
- Penido MG, Tavares Mde S. (2015, Sep 6). Pediatric primary urolithiasis: Symptoms, medical management and prevention strategies. *World J Nephrol.* 4(4): 444-54. doi: 10.5527/wjn.v4.i4.444.
- Koyuncu H, Yencilek F, Erurhan S, Erydyirim B, Sarica K. (2011). Clinical course of pediatric urolithiasis: follow up data in a long term basis. *Int. Urol. Nephrol.* 43: 7-13.
- Bras J. (2016, Jan./Mar). *Jornal Brasileiro de Nefrologia.* 38, 1. <http://dx.doi.org/10.5935/0101-2800.20160014>
- Horuz R., Sarica K. (2012, Sep 10). The management of staghorn calculi in children. *Arab J Urol:* 330-335.
- Zargooshi J. (2001). Open stone surgery in children. Is it justified in the era of minimally invasive therapies? *BJU Int.* 88: 928-31.
- Jurkiewicz B., Ząbkowski T., Jobs K., Samotyjek J., Jung A. (2016, Apr 16). Combined Use of Pyelolithotomy and Endoscopy: An Alternative Surgical Treatment for Staghorn Urolithiasis in Children *Urol J.* 13(2): 2599-604.

Відомості про авторів:

Wajszczuk Ewa – Department of Pediatric Surgery and Pediatric Urology, Centre of Postgraduate Medical Education, Dziekanów Leśny, Warsaw, Poland.

Szymanek-Szwed Magdalena – Department of Pediatric Surgery and Pediatric Urology, Centre of Postgraduate Medical Education, Dziekanów Leśny, Warsaw, Poland.

Samotyjek Joanna – Department of Pediatric Surgery and Pediatric Urology, Centre of Postgraduate Medical Education, Dziekanów Leśny, Warsaw, Poland.

Jobs Katarzyna – Department of Pediatrics and Nephrology, Military Medical Institute, Warsaw, Poland.

Jurkiewicz Beata – prof. CMKP, Head of the Department of Paediatrics, Nephrology and Allergology, Centre of Postgraduate Medical Education, Dziekanów, Warsaw, Poland.

Стаття надійшла до редакції 02.02.2019 р., прийнята до друку 24.06.2019 р.