

UDK 616.34-007.272-053.2-074

R.A. Khan, R. Ara, Sh. Wahab, I. Ahmad

Ultrasound in pediatric intestinal obstruction: Assessing its full potential

Jawaharlal Nehru Medical College of Aligarh Muslim University, Aligarh, India

Paediatric surgery.Ukraine.2019.4(65):19-24; DOI 10.15574/PS.2019.65.19

For citation: Khan RA, Ara R, Wahab Sh, Ahmad I. (2019). Ultrasound in pediatric intestinal obstruction: Assessing its full potential. Paediatric Surgery.Ukraine. 4(65): 19-24. doi 10.15574/PS.2019.65.19

Diagnosis of intestinal obstruction in children, one of the commonest surgical emergencies, may still test the acumen of the attending clinician. Any delay in diagnosis may lead to complications which carry high morbidity or may even be fatal. Besides clinical judgment, radiography plays an important role in the diagnosis. Ultrasonography, although not the investigation of choice but it does give an initial suggestion of the diagnosis in the child without any harmful effects of radiation.

The authors declare they have no conflict of interest

Key words: Intestinal Obstruction, Children, Ultrasonography.

Ультрасонографія за непрохідності кишечника у дітей: оцінка повного потенціалу

R.A. Khan, R. Ara, Sh. Wahab, I. Ahmad

Jawaharlal Nehru Medical College of Aligarh Muslim University, Aligarh, India

Кишкова непрохідність у дітей є однією з найбільш розповсюджених невідкладних ситуацій у хірургії, а її діагностика вимагає інтуїції лікуючого лікаря. Будь-яка затримка діагностування може призвести до ускладнень, високої захворюваності або навіть летального наслідку. Окрім клінічної оцінки, рентгенографія відіграє важливу роль у діагностиці. Ультрасонографія, хоча й не є основним дослідженням вибору, дає можливість зробити попереднє припущення про діагноз дитини, не піддаючи її шкідливому впливу радіації.

Ключові слова: непрохідність кишечника, діти, ультрасонографія.

Ультрасонография при непроходимости кишечника у детей: оценка полного потенциала

R.A. Khan, R. Ara, Sh. Wahab, I. Ahmad

Jawaharlal Nehru Medical College of Aligarh Muslim University, Aligarh, India

Кишечная непроходимость у детей является одной из самых распространенных неотложных ситуаций в хирургии, а её диагностика требует проницательности лечащего врача. Любая задержка в постановке диагноза может привести к осложнениям, высокой заболеваемости или даже летальному исходу. Помимо клинической оценки, рентгенография играет важную роль в диагностике. Ультрасонография, хотя и не является основным исследованием выбора, даёт возможность получить предварительное предположение о диагнозе у ребенка, не подвергая его вредному воздействию радиации.

Ключевые слова: непроходимость кишечника, дети, ультрасонография.

Background and Introduction

Intestinal obstruction in children is one of the most common surgical emergencies. It is a potentially life threatening condition, if not diagnosed and managed timely. It can lead to complications like necrosis of bowel, perforation or sepsis. Hence, early and proper diagnosis and management is very important.

Diagnosis is mainly based on detailed clinical history and examination, radiography, fluoroscopy, abdominal sonography. CT scan is the gold standard for evaluation of these patients but sonography still remains the main

stay of diagnosis in our subcontinent. In Indian scenario, the diagnosis of intestinal obstruction is usually made by clinical evaluation of patient followed by plain abdominal radiography which may show dilated bowel loops and multiple air fluid levels. In spite of low diagnostic yield [4] it continues to be the initial method of imaging to serve as a basis for triage for further imaging work up. Ultrasonography is an ideal imaging modality in paediatric population because it conveys image in real time, is noninvasive, relatively cost effective and without ionizing radiation. Also, sonography requires no sedation in

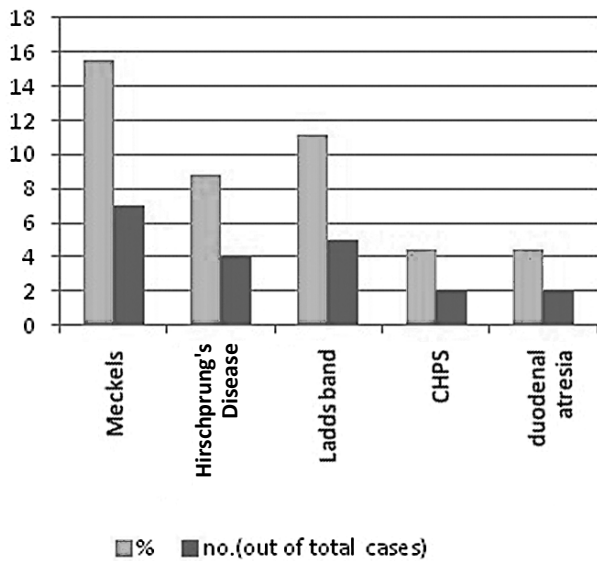


Fig. 1. Congenital causes of intestinal obstruction

most of the cases [1]. **The purpose** of this study is to evaluate the role of abdominal sonography in diagnosing the intestinal obstruction and its causes and to correlate the abdominal sonography diagnosis with clinical and surgical outcomes.

Materials and Methods

The study was done on 57 children (neonates – 14 years) who presented in casualty/OPD of paediatric surgery department of JNMCH, AMU, Aligarh for from October 2016 to October 2018 with complaints of pain abdomen, abdominal distension, vomiting, not passing stool, or any clinical features suggestive of intestinal obstruction. Informed consent of patients was obtained and a detailed clinical history and examination was done.

Imaging evaluation was done by x-ray abdomen-erect and supine views & abdominal sonography on SAMSUNG SONOACE R 7 equipped with 3-5 MHZ curvilinear and 5-12 MHZ linear probe.

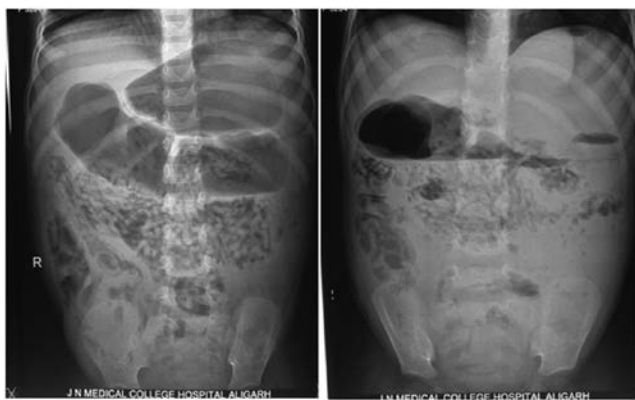

Fig. 2. X-ray abdomen (supine and erect) of a child of 5 years of age with history worms infestation showing dilated small bowel loops and stomach gas shadow showing air fluid level with mottled appearance in most of the loops

Patient was examined in supine position without any special preparation. First curvilinear probe was used for general overview of abdomen and also to rule out any solid organ /non bowel pathologies. Following that, linear probe was used for bowel imaging. Small bowel was predominantly looked for in the centre of abdomen, and right iliac fossa. Large bowel loops were scanned though out their visualized course. Bowel loops which were gas/fluid filled and were hindering looking for underlying pathology were displaced by graded compression technique [1].

To summarize the important finding of bowel imaging, the following basic points were evaluated in each of our cases; dilated bowel loops, wall thickness, gut signature, peristalsis pattern, transition point, extraintestinal fluid, echoes/septae in extraintestinal fluid and other findings. The findings on abdominal sonography were tabulated and analyzed with clinical & surgical outcome.

Observations

Seven of these cases were excluded from study after clinical and radiographic evaluation as these cases had unstable hemodynamics and showed free air under diaphragm on plain radiography and were directly taken for surgical intervention without abdominal sonography. Out of 50 cases, 36 were male and 14 were females with male to female ratio ~2.5:1. The age group of patients most frequently affected were between 1 month and 1 year – 17 (34%), followed by neonatal group 11 (22%) patients. Abdominal distension in 38 (76%) and not passing stool in 37 (74%) cases were the most common presenting clinical features which was followed by pain abdomen in 38 (76%), vomiting in 11 (22%) and blood with mucus in stools in 4 (6%) patients.

Final diagnosis was made in 45 patients after clinical evaluation, radiography, abdominal sonography and surgical outcome. Five patients were managed conservatively as no definite etiology could be made. Out of 45 cases, etiology in 20 (44%) was congenital and in 25 (56%) cases it was acquired. Overall most common cause came out to be intussusception, Meckel's diverticulum and infective causes. Among congenital causes most common cause was Meckel's diverticulum, followed by Ladd's band, Hirschprung's disease and congenital hypertrophic pyloric stenosis. In acquired causes, most common cause was intussusception (Fig. 1). In neonatal age group, Ladd's band and Hirschprung's disease were the most common cause. Beyond neonatal age group, most common cause was intussusception and appendicitis.

On plain radiographic evaluation twenty patients showed nonspecific/normal findings. About 26 patients showed both features of dilated small bowel loops and multiple air fluid level suggesting intestinal obstruction (Fig. 2).

Table 1
Abdominal sonography findings

	No. of cases	% of cases
Dilated small bowel loops	35	70
Dilated small and large bowel	4	8
Ineffective/abnormal peristalsis	28	56
Wall thickness		
a) normal (~3mm)	42	84
b) increased	4	8
c) thinned	0	0
Transition point	21	42
Extraintestinal Fluid	39	78
Echoes/Septae in fluid	1	2

On sonographic evaluation, significantly dilated small loops were seen in 35 cases. In 4 cases, both large and small bowel loops were dilated. Most of the bowel loops were fecal loaded and fluid filled with hyperechoic spots (gas). Ineffective i.e. sluggish and to and fro peristalsis pattern was seen in 28 cases. Hyperactive peristalsis could not be documented in any of our cases which may be due to very late presentation of patients of mechanical intestinal obstruction in our hospital. Wall thickness was increased in 4 of our cases and rest showed almost normal (~3 mm) thickness in our study. We looked for underlying pathology for dilated/obstructed bowel loops and transition point could be well documented only in 21 patients. These were the cases of intussusception, congenital hypertrophic pyloric stenosis, worm infestation and appendicitis (Fig. 3, 4). This decreased number could be due to excessively gas /fluid filled bowel loops which hindered looking into underlying pathology/transition point despite of graded compression used to displace the gas/fluid. Gut signature was maintained in almost all cases. No evidence of loss of mural stratification was noted which could suggest malignancy. Presence of extraintestinal fluid was noted in 39 (78%) of our cases and conglomerated mesenteric nodes predominantly in right iliac fossa was seen in 4 cases (Table 1). Most common diagnosis observed in our study was of intussusceptions, subacute intestinal obstruction, congenital hypertrophic pyloric stenosis, appendiceal causes of obstruction and worm infestations (Table 2). In five cases, no definite diagnosis could be made and these cases were showing sluggish peristalsis with normal calibre of bowel loop (non-mechanical cause) and few having non-specific enlarged oval non necrotic and discrete mesenteric lymph nodes. So, these cases were given medical management. In 5 out of 50 cases, no definite diagnosis could be made; they were kept on conservative management and were relieved of their symptoms. Forty five underwent laparotomy and

Table 2
Percentage of cases of different etiology

Diagnosis	NO.	% of cases
Intussusception	11	22
Small bowel obstruction with no definite transition point and normal bowel wall	12	24
Small bowel obstruction with edematous/gangrenous loops	4	8
Congenital hypertrophic pyloric stenosis	2	4
Appendicitis and its complications	4	8
Worm infestation	2	4
Enlarged & conglomerated Mesenteric lymph nodes with obstruction	4	8
Abdominal distension d/t large bowel dilatation	4	8
Dilated stomach and visualized part of duodenum	2	4
No definite etiology	5	10

Table 3
Peroperative diagnosis

Surgical outcome	No.(out of 45)	%
Intussusception	11	24.4
Meckel's diverticulum	7	15.5
Congenital bands	5	11.1
Hirschprung's disease	4	8.8
Hypertrophic pyloric stenosis	2	4.4
Worm infestation	2	4.4
Appendicitis/perforated appendix	4	8.8
Gangrenous bowel	4	8.8
Inflamed and conglomerated Mesenteric nodes with intestinal obstruction	4	8.8
Duodenal atresia	2	4.4

operative treatment. Peroperative findings seen at laparotomy and the surgical procedures done in these cases are tabulated below (Tables 3, 4).

Comparison of surgical and sonographic findings

We compared the peroperative findings with the abdominal sonographic findings (Table 5). In terms of findings, abdominal sonography showed 100% sensitivity in cases of dilated bowel loops and conglomerated mesenteric nodes and ~ 93% sensitivity in detecting interbowel free fluid. In terms of making the diagnosis of the cause of obstruction abdominal sonography showed 100% sensitivity in case of intussusception, congenital hypertrophic pyloric stenosis, worm infestation, gangrenous bowel, interbowel free fluid and appendicitis and its complications. However abdominal sonography was less sensitive in picking up transition point (65.2%). There can be

Оригінальні дослідження. Абдомінальна хірургія

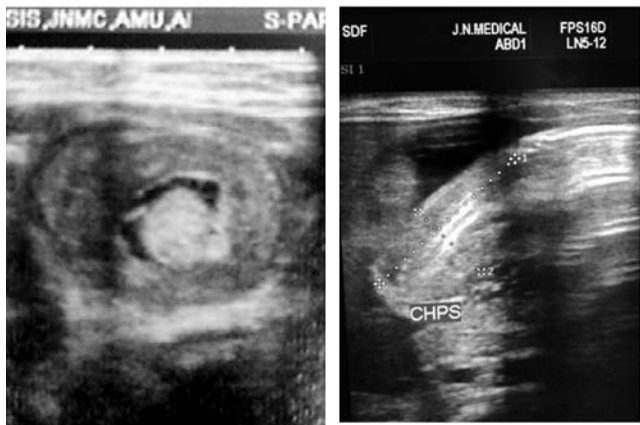


Fig. 3. Target sign on transverse ultrasound of an intussusception. The concentric layers of the mass represent the different tissues in the bowel wall of the intussusceptum and the intussusciptens

Fig. 4. CHPS – The pylorus shows thickened muscle layer and also elongated indicative of hypertrophic pyloric stenosis

myriad of reasons for this, some being presence of excessive gas, patient’s clinical condition and compliance and in general sensitivity of abdominal sonography in detecting the cases of Meckel’s diverticulum, congenital bands and Hirschprung’s disease was low.

Discussion

Intestinal obstruction in pediatric age group can be broadly categorized into: neonatal and non neonatal age group. Male to female ratio our study came out to be ~2.5:1. Reason for male sex predominance is not known, but it may be due to less attention towards female child by social custom in our society. Most common age group involved in our study was 1month to 1 year (34%) followed by neonatal age group (22%) [3,7,8]. Uba et al also studied and observed that 74% of patients were less than 1year [11]. Abdominal distension & pain was most common presenting complaints (76%) in our study group. On the basis of x-ray finding in our study, 26 patients were suspected of intestinal obstruction; however no definite cause of obstruction could be made out on basis of x-ray. Final diagnosis was made on 45 patients after clinical evaluation, radiography, abdominal sonography and surgical outcome. 5 patients were managed conservatively and few of them had no proper provisional diagnosis. Out of 45 cases, 20 were congenital and 25 cases were acquired.

In our study 11 (24.4%) children were finally diagnosed as having intussusception, 7 (15.5%) were diagnosed Meckel’s diverticulum, 5 (11.1%) were diagnosed with congenital bands, 4 cases of Hirschprung’s disease, 4 (8.8%) had gangrenous bowel on surgical outcome, 4 (8.8%) had necrotic and conglomerated mesenteric

Table 5

Comparison of Peroperative and sonographic diagnosis

	Peroperative finding (No. of cases)	Abdominal sonographic findings	Percentage sensitivity
Dilated bowel loops	35	35	100
Interbowel free fluid	42	39	93.3
Transition point	45	21	65.2
Conglomerated mesenteric nodes	4	4	100
Intussusception	11	11	100
Congenital hypertrophic pyloric stenosis	2	2	100
Worm infestation	2	2	100
Appendicitis and its complications	2	2	100
Gangrenous bowel	4	4	100

Table 4

Surgical Procedures done

Procedures done	No of cases	Percentage
Exploratory laprotomy with reduction of intussusception	9	20
Laprotomy with resection and anastomosis for intussusception	2	4.4
Resection & anastomosis of gangrenous loop and conglomerated mesenteric nodes	8	17.8
Resection and anastomosis of bowel segment for Meckel’s diverticulum	7	15.5
Colostomy	4	8.8
Enterotomy with removal of worms	2	4.4
Laposcopic Pyloromyotomy	2	4.4
Appendectomy	4	8.8
Ladd’s band release	5	11.1
Duodenoduodenostomy	2	4.4

lymphadenitis with associated bowel obstruction, 2 (4.4 %) had hypertrophic pyloric stenosis, 4 (8.8%) had acute appendicitis, 2 (4.4%) had duodenal atresia and 2 (4.4%) were diagnosed with worm infestation. Five children had no specific diagnosis on abdominal sonography, so they were managed conservatively. In our study, most common etiology in neonatal age group was Ladd’s band and Hirschprung’s disease followed by congenital hypertrophic pyloric stenosis and duodenal atresia. In non neonatal age group, most common etiology came out to be Hirschprung’s disease.

Among congenital causes, most common cause was Meckel’s diverticulum, followed by Ladd’s band and

Hirschsprung's and congenital hypertrophic pyloric stenosis. Overall most common cause came out to be intussusception, Meckel's and infective causes. A study was conducted by Soomro et al. in 2011 on 55 cases in which most common cause was intussusceptions (27%), Meckel's diverticulum and band (~16.4 %) and obstructed hernias (14.5 %) [6,10]. On abdominal sonography, besides making the diagnosis of presence of obstruction, we were also able to find the transition points, which was causing obstruction and these cases were of intussusception, congenital hypertrophic pyloric stenosis & worm infestation & appendicial causes. We also observed that intussusception was most common cause of overall of intestinal obstruction. Those cases which on surgical outcome came out to be intussusception were also given provisional diagnosis of intussusception, thus making the abdominal sonography sensitivity of 100%. Abdominal sonography findings were typical showing concentric/doughnut appearance on transverse section and fork sign on longitudinal section. Most of them were ileocecal type with average age group of 1 year. Two cases of idiopathic hypertrophic pyloric stenosis were also reported on abdominal sonography, which were confirmed with surgical finding with diagnostic accuracy of 100%. Abdominal sonography findings were increased pyloric length between 21-24 mm, and muscle thickness between 4-6 mm, giving nipple sign on longitudinal scan and doughnut appearance on axial scan.

It has been shown that the pyloric length is the only precise indicator of hypertrophic pyloric stenosis. Pylorospasm is also documented to be a common finding in this age group where follow up ultrasound shows decreasing pyloric thickness below 2 mm [3]. Two cases of worm infestation were noted in our study which showed 100% diagnostic accuracy on abdominal sonography. X-ray showed air-fluid levels suggestive of intestinal obstruction. Abdominal sonography revealed masses in the intestinal lumen with parallel paired lines on longitudinal views and 'bull's eye' appearance on transverse section. Two cases of duodenal atresia were also reported, both were male child of less than one month. Duodenal/Ileal atresia was suggested as a diagnosis and was confirmed at operation, thereby emphasizing the vital role of abdominal sonography in intestinal disorders.

In a prospective study by Mardan et al. in 2007 on 200 patients, laparotomy done on clinical assessment alone for acute appendicitis resulted in 22.5% negative appendectomy. In the same study involving 200 patients, laparotomy done on combined clinical and ultrasound findings resulted in only 4.7% negative appendectomy.

This study proved that routine ultrasound examination by graded compression technique can significantly improve the diagnostic accuracy and reduce the surgeon's burden as well as postoperative morbidity [5]. Ultrasound is widely accessible, inexpensive, non-invasive, and portable with high spatial and temporal resolution. It is not only a very sensitive but a specific modality for the diagnosis of intestinal obstruction in children. There is a trend of increased use of sonography in initial assessment of paediatric patients with intestinal obstruction as abdominal sonography can also be repeated at short intervals & as a bedside procedure that further increases its accuracy & improves patient management.

The major limitation of gastrointestinal tract sonography is the decreased sensitivity of visualization of transition points and no to very low sensitivity in picking up important causes like Meckel's and congenital bands due to many factors including interposed bowel gases, incomppliance, and also less penetration power of probe [5,9].

Even then, it overweighs its outcome. It can be easily done as bedside procedure and repeated sonography can be done for follow up as it has no radiation hazard problem, thereby increasing the accurate diagnostic outcome. Also, now advanced high frequency probes have come into existence with frequency of more than 18 MHz having very high resolution hence giving more detailed anatomical information [2].

Bowel wall perfusion can also be assessed by Doppler sonography. Differentiating between simple and strangulating obstruction is very important as patient's condition in strangulated obstruction deteriorates quickly and hence requires early detection to avoid necrosis and preserve that bowel segment. Significant decrease in the end diastolic volume and increase in the resistive index for the SMA in strangulating obstruction is a marker for urgent laparotomy [4].

Conclusions

Abdominal sonography is more sensitive in diagnosing intestinal obstruction, its complications as well as the etiopathogenesis behind it. There is no harm of radiation as well as no need of sedation as compared to CT scan. Its favorable cost, availability, flexibility, and user friendliness, as well as its high temporal and spatial resolution further enhance the utility of sonography in most of the cases of pediatric intestinal obstruction. Abdominal sonography helps in assisting the surgeons with important sonographic findings which suggest early operative intervention: intra peritoneal fluid, bowel thickness (>4 mm), decreased/absent peristalsis in previous hyperactive bowel. Also if needed abdominal sonography

Оригінальні дослідження. Абдомінальна хірургія

guided aspiration can be done, and if it contains red blood cells, it may indicate gangrenous bowel suggesting urgent surgery which proves to be life saving. Serial abdominal sonography examinations can be done in cases which are managed conservatively without any radiation hazards.

To conclude, systematic approach and expertise in abdominal sonography has the potential of significantly reducing mortality and morbidity among children of intestinal obstruction.

The authors declare they have no conflict of interest.

References/Література

1. Bachur RG, Callahan MJ, Monuteaux MC, Rangel SJ. (2015). Integration of ultrasound findings and clinical score in the diagnostic evaluation of pediatric appendicitis. *J Pediatr*. 166: 1134–1139
2. Hefny AF, Corr P, Abu-Zidan FM. (2012). The role of ultrasound in the management of intestinal obstruction. *J Emerg Trauma Shock*. 5(1): 84-6.
3. Hussain M. (2008). Sonographic Diagnosis of Infantile Hypertrophic Pyloric stenosis- Use of Simultaneous Grey-scale & Colour Doppler Examination. *Int J Health Sci (Qassim)*. 2(2): 134-40.
4. Jabra AA, Eng J, Zaleski CG, Abdenour GE Jr, Vuong HV, Aid-eyan UO, Fishman EK. (2001). CT of small-bowel obstruction in children: sensitivity and specificity. *AJR Am J Roentgenol*. 177(2): 431-6.
5. Mardan MAA, Mufti TS, Khattak IU, Chilkunda N, Alshayeb AA, Mohammed AM et al. (2007). Role of ultrasound in acute appendicitis. *JAMC*. 19(3): 72-9.
6. Nylund K, Ødegaard S, Hausken T, Folvik G, Lied GA, Viola I, et al. (2009). Sonography of the small intestine. *World J Gastroenterol*. 15: 1319–30.
7. Ogunloyin OO, Afolabi AO, Ogunlana DI, Lawal TA, Yifeyeh AC. (2009). Pattern and outcome of childhood intestinal obstruction at a tertiary hospital in Nigeria. *Afr Health Sci*. 9(3): 170-3.
8. Ratan SK, Rattan KN, Pandey RM, Sehgal T, Kumar A, Ratan J. (2006). Surgically treated gastrointestinal obstruction in children: causes and complications. *Indian J Gastroentero*. 25: 320-1.
9. Schmidt T, Hohl C, Haage P, Honnef D, Mahnken AH, Krombach G, Piroth W, Günther RW. (2005). Phase-inversion tissue harmonic imaging compared to fundamental B-mode ultrasound in the evaluation of the pathology of large and small bowel. *Eur Radiol*. 15(9): 2021-30.
10. Soomro S, Mughal SA. (2013). Intestinal obstruction in children. *J Surg Pak Int*. 18(1): 20-23.
11. Uba AF, Edino ST, Yakubu AA, Sheshe AA. (2004). Childhood intestinal obstruction in Northwestern Nigeria. *West Afr J Med*. 23: 314-8.

Відомості про авторів:

Khan Rizwan Ahmad – MS, MCh, Associate Professor, Dept of Pediatric Surgery, JNMCH, AMU, Aligarh, U.P., India.

Ara Roshan – Junior Resident, Dept of Radiodiagnosis, JNMCH, AMU, Aligarh, U.P., India.

Shagufta Wahab – MD, Associate Professor, Dept of Radiodiagnosis, JNMCH, AMU, Aligarh, U.P., India. Ph. No. +91 9410210281; Email: drshaguftawahab@rediffmail.com

Ibne Ahmad – MD, Professor, Dept of Radiodiagnosis, JNMCH, AMU, Aligarh, U.P., India.

Стаття надійшла до редакції 16.09.2019 р., прийнята до друку 03.11.2019 р.



1st Fetal Surgery Symposium and hands on course March 2–25, 2020 Barcelona, Spain

Directors: Dr. Elena Carreras, Head of Obstetric Department Vall d'Hebron Barcelona Hospital Campus
Dr. Manuel López, Head of Pediatric Surgery Department Vall d'Hebron Barcelona Hospital Campus

Comments: Hands-on group 1 (24 and 25/03/20): FULL REGISTRATIONS
Hands-on group 2 (26 and 27/03/20)

The registration includes: Attendance, Official Meeting Documents, lunch and coffee breaks.
Please let us know of any allergies or special dietary requirements you may have when you make your registration form.

Information: Aula Vall d'Hebron
Mail: inscripcionesaulavh@vhebron.net
Tel: 93 489 45 68

Venue: Conference room – Pabellón Docente 1st floor
Hospital Universitari Vall d'Hebron
Paseo Vall d'Hebron, 119 – 129
Barcelona (Spain)